

# Lateral open bite: Treatment and stability

Marise de Castro Cabrera,<sup>a</sup> Carlos Alberto Gregório Cabrera,<sup>a</sup> Karina Maria Salvatore de Freitas,<sup>a</sup> Guilherme Janson,<sup>b</sup> and Marcos Roberto de Freitas<sup>c</sup>

Bauru, Brazil

Because of their multifactorial etiologies, dental and skeletal open bites are among the most difficult malocclusions to treat to a successful and stable result. Etiologic factors include vertical maxillary excess, skeletal pattern, abnormalities in dental eruption, and tongue-thrust problems. The purpose of this article was to report the treatment of an adult patient with a lateral open bite and a unilateral posterior crossbite. The treatment involved nonextraction therapy, including intermaxillary elastics, to obtain dentoalveolar extrusion in the region of the lateral open bite. The treatment results were successful and remained stable 2 years later. (*Am J Orthod Dentofacial Orthop* 2010;137:701-11)

**T**reatment of an open bite malocclusion can be difficult for the orthodontist, because it develops as a result of the interplay of many etiologic factors.<sup>1-3</sup> Etiologic factors generally cited in the literature include vertical maxillary excess, skeletal pattern, abnormalities in dental eruption, and tongue-thrust problems. In adults, the mechanical treatment options are limited. Orthognathic surgery is indicated in adult patients with severe open bite and unesthetic facial proportions. For less severe problems, the search for effective treatment modalities continues.<sup>1</sup>

Lateral open bite is rarely observed, especially in adults. In some patients, lateral open bite is due to a disturbance of the eruption mechanism itself, so that non-ankylosed teeth cease to erupt.<sup>4</sup> Few lateral open bite cases are reported in the literature, and all involved ankylosed teeth or primary failure of eruption.<sup>4-7</sup> In this case report, we present the treatment of a patient with a lateral open bite and a unilateral posterior crossbite, treated with fixed appliances and intermaxillary elastics. The treatment results were satisfactory and stable 2 years after the end of active treatment.

## DIAGNOSIS AND ETIOLOGY

An 18-year-old man came for orthodontic treatment to the private orthodontic office of the first author

(M.C.C.) with a unilateral open bite and a posterior crossbite in centric relation as determined by bilateral manipulation<sup>8</sup> (Fig 1). His chief complaints were an unsatisfactory occlusion, chewing difficulty, and smile esthetics. He reported a tongue-thrusting habit in the open-bite space; this indicated that the lateral open bite was caused by mechanical interference in tooth eruption. There was no previous history of this type of malocclusion in his family, and he had no temporomandibular disorder symptoms.

Clinically, the patient had unstrained lip closure, left lateral open bite, and left posterior crossbite (Fig 1). The initial intraoral photographs and dental casts showed a Class I molar relationship on the right side and a Class II molar relationship on the left side, causing a slight maxillary-to-mandibular midline deviation, an overjet of 2 mm, and a left lateral open bite of 3 mm (Figs 1 and 2). The maxillary arch was mildly crowded, and the mandibular arch had mild spacing. The left mandibular third molar was impacted (Fig 3).

The cephalometric analysis showed a convex skeletal profile, an open gonial angle, a narrow and long mandibular symphysis characteristic of the doliofacial pattern, a deficient maxillomandibular relationship, well-positioned maxillary incisors, and protruded and labially tipped mandibular incisors (Fig 4, Table).

## TREATMENT OBJECTIVES

The main objectives of the orthodontic treatment were to close the lateral open bite and to correct the left posterior crossbite, to achieve Class I molar and canine relationships on the left side and ideal overjet and overbite. Treatment also aimed to achieve “the 6 keys to normal occlusion”<sup>9</sup> and a mutually protected occlusion,<sup>10</sup> to provide satisfactory facial esthetics and masticatory function, to eliminate the abnormal tongue thrust, and to achieve stable treatment results.

From the Department of Orthodontics, Bauru Dental School, University of São Paulo, Bauru, São Paulo, Brazil.

<sup>a</sup>Graduate student.

<sup>b</sup>Professor and head.

<sup>c</sup>Professor.

The authors report no commercial, proprietary, or financial interest in the products or companies described in this article.

Reprint requests to: Karina Maria Salvatore de Freitas, Department of Orthodontics, Bauru Dental School, University of São Paulo, Al. Octávio Pinheiro Brisolla, 9-75, Cep 17012-901, Bauru, São Paulo, Brazil; e-mail, [kmsf@uol.com.br](mailto:kmsf@uol.com.br).

Submitted, June 2007; revised and accepted, November 2007.

0889-5406/\$36.00

Copyright © 2010 by the American Association of Orthodontists.

doi:10.1016/j.ajodo.2007.11.037

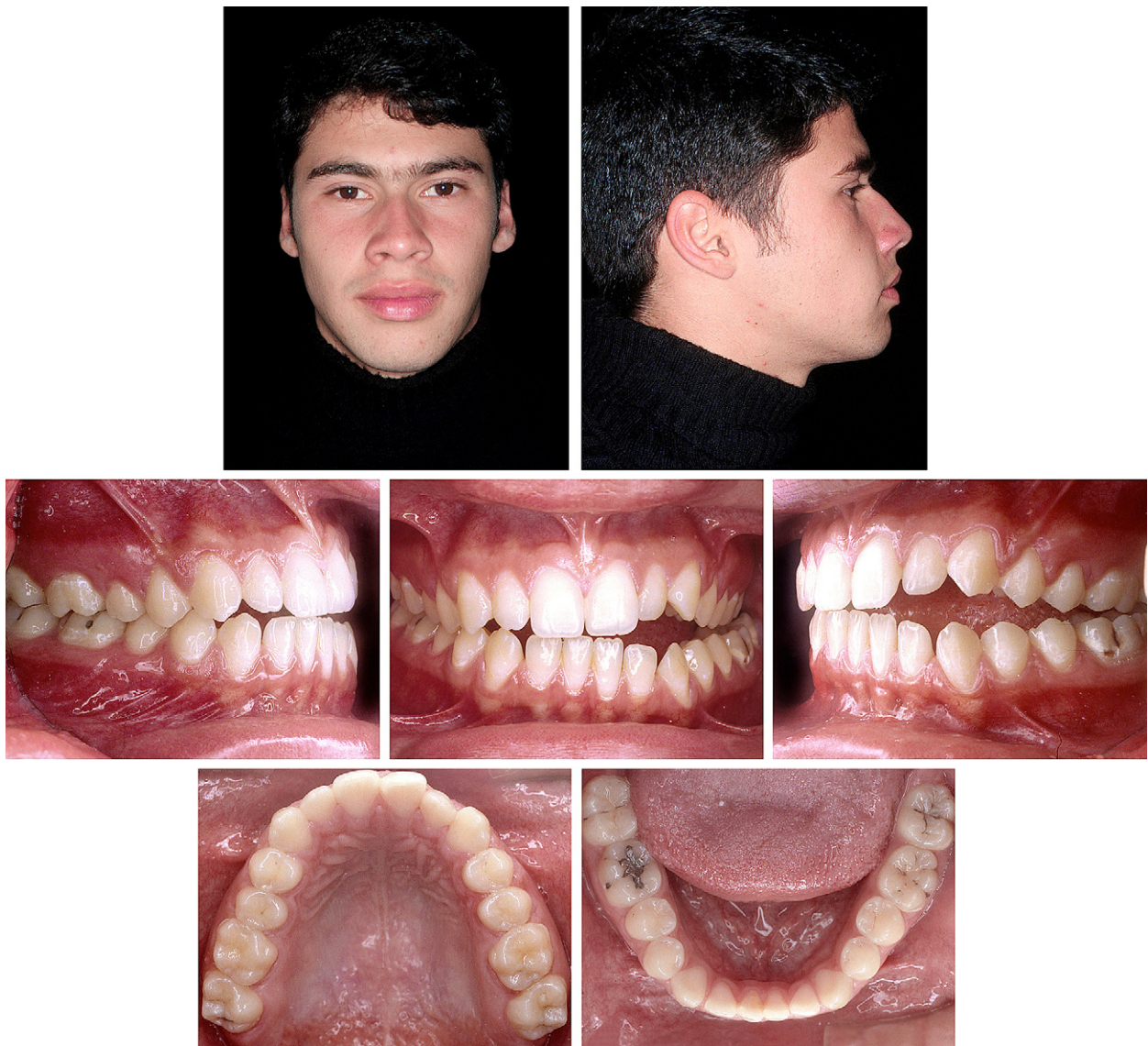

Fig 1. Pretreatment extraoral and intraoral photographs.

### TREATMENT ALTERNATIVES

One treatment option was nonextraction therapy, including intermaxillary elastics to correct the left posterior crossbite and to obtain dentoalveolar extrusion in the region of the lateral open bite.

Another treatment option consisted of surgically assisted rapid maxillary expansion to correct the left posterior crossbite and subsequent use of intermaxillary elastics to close the lateral open bite. Rapid maxillary expansion without surgical assistance was also a treatment option, in spite of the patient's age, to achieve at least buccal inclination of the maxillary posterior teeth.

The patient rejected the surgically assisted rapid maxillary expansion and preferred the first treatment alternative.

### TREATMENT PLANNING

Because the patient had an acceptable profile and minimal arch-length discrepancy, nonextraction treatment was planned. The left posterior crossbite would be corrected with intermaxillary elastics. The lateral open bite would be closed by extruding the maxillary left lateral incisor, canine, and premolars. Because this procedure is reportedly prone to relapse,<sup>11,12</sup> he would need myofunctional therapy after the orthodontic treatment.<sup>13</sup>

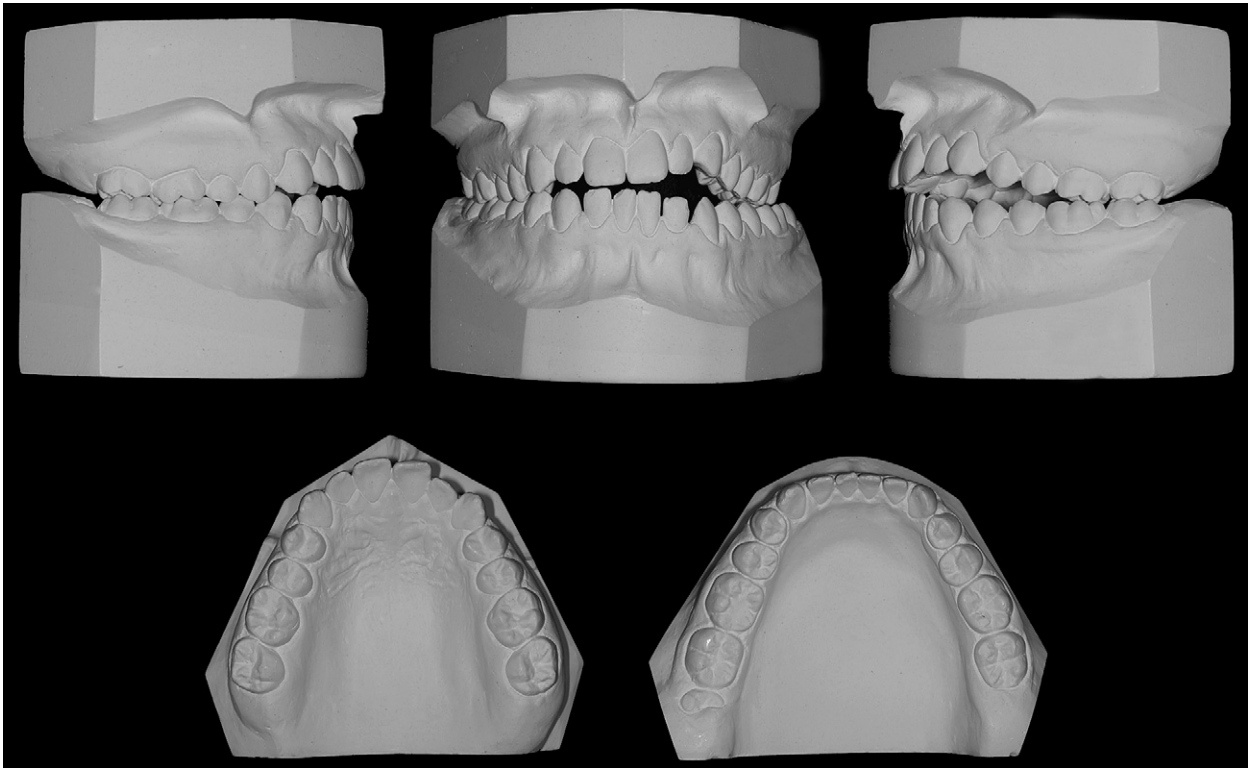


Fig 2. Pretreatment dental casts.

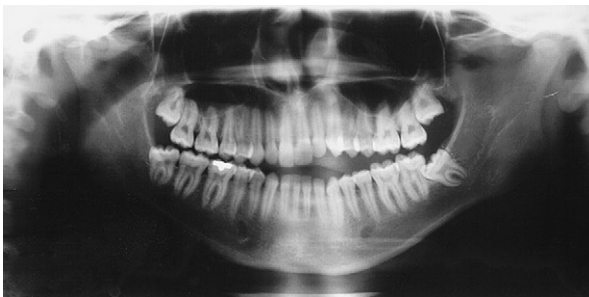

Fig 3. Pretreatment panoramic radiograph.

#### TREATMENT PROGRESS

All third molars were extracted before fixed appliance placement. Treatment was started simultaneously in the mandibular and maxillary arches, with a straight-wire appliance (0.022 × 0.028 in, A Company, San Diego, Calif). Initially, nickel-titanium archwires were used (0.016 and 0.018 in). After 4 months of treatment, when the teeth were relatively level and aligned, stainless steel archwires were used (0.014, 0.016, and 0.018 in), and the maxillary archwire was slightly expanded in the posterior region. At this time, intermaxillary elastics were used from the palatal buttons on the

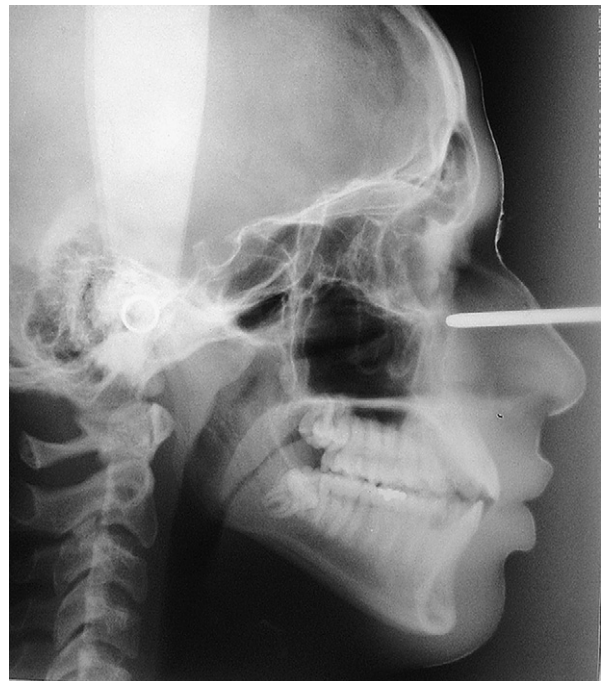
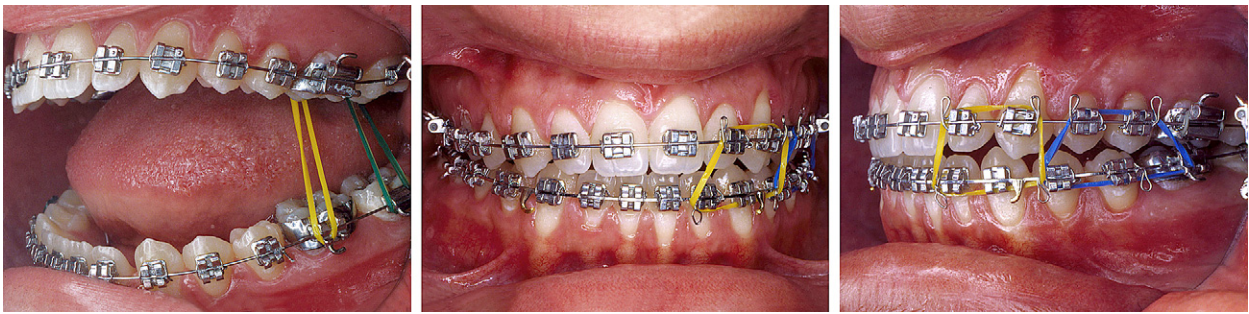


Fig 4. Pretreatment lateral cephalogram.



**Fig 5.** Intraoral progress photographs show the use of intermaxillary elastics to correct the left posterior crossbite and vertical elastics to close the left lateral open bite.

bands of the left maxillary molars to the buccal hooks on the mandibular left molars. These intermaxillary elastics helped to correct the posterior crossbite (Fig 5). Subsequently, vertical intermaxillary elastics were used in 2 dental segments: 1 linking the maxillary and mandibular left lateral incisor and canines, and the other linking the maxillary and mandibular left premolars and first molars (Fig 5). The patient was instructed to change the elastics daily. Intermaxillary elastics were used for 5 months until a normal vertical bite relationship was achieved. Because the maxillary incisal and posterior occlusal planes were oblique and not parallel to the interpupillary line, and the mandibular incisal and posterior occlusal planes were slightly canted in the opposite direction, rectangular archwires were used in the mandibular arch and round archwires in the maxillary arch, with vertical elastics, to allow bite closing with greater extrusion of the maxillary teeth and less extrusion of the mandibular teeth, while correcting the asymmetric canting of both dental arches<sup>14</sup> (Fig 5). After open-bite closure, the vertical elastics were maintained for an additional 5 months. Thereafter, the elastics were removed, and leveling archwires were placed for 5 months to determine the open-bite relapse potential. The Class II molar relationship on the left side was corrected with Class II elastics during the alignment phase. After the fixed appliances were removed, a modified Hawley retainer was placed in the maxillary arch, a canine-to-canine mandibular retainer was bonded, and the patient received myofunctional therapy. Active treatment time was 2 years 9 months.

## TREATMENT RESULTS

The posttreatment intraoral photographs show a 2-mm overbite and good interdigitation of the lateral segments. The facial profile showed a slight improvement, and Class I canine and molar relationships were obtained. There was no obvious evidence of root resorp-

tion. The mandibular left central incisor showed recession, possibly caused by trauma during oral hygiene (Figs 6-9, Table). Periodontal surgery was recommended to cover the root.

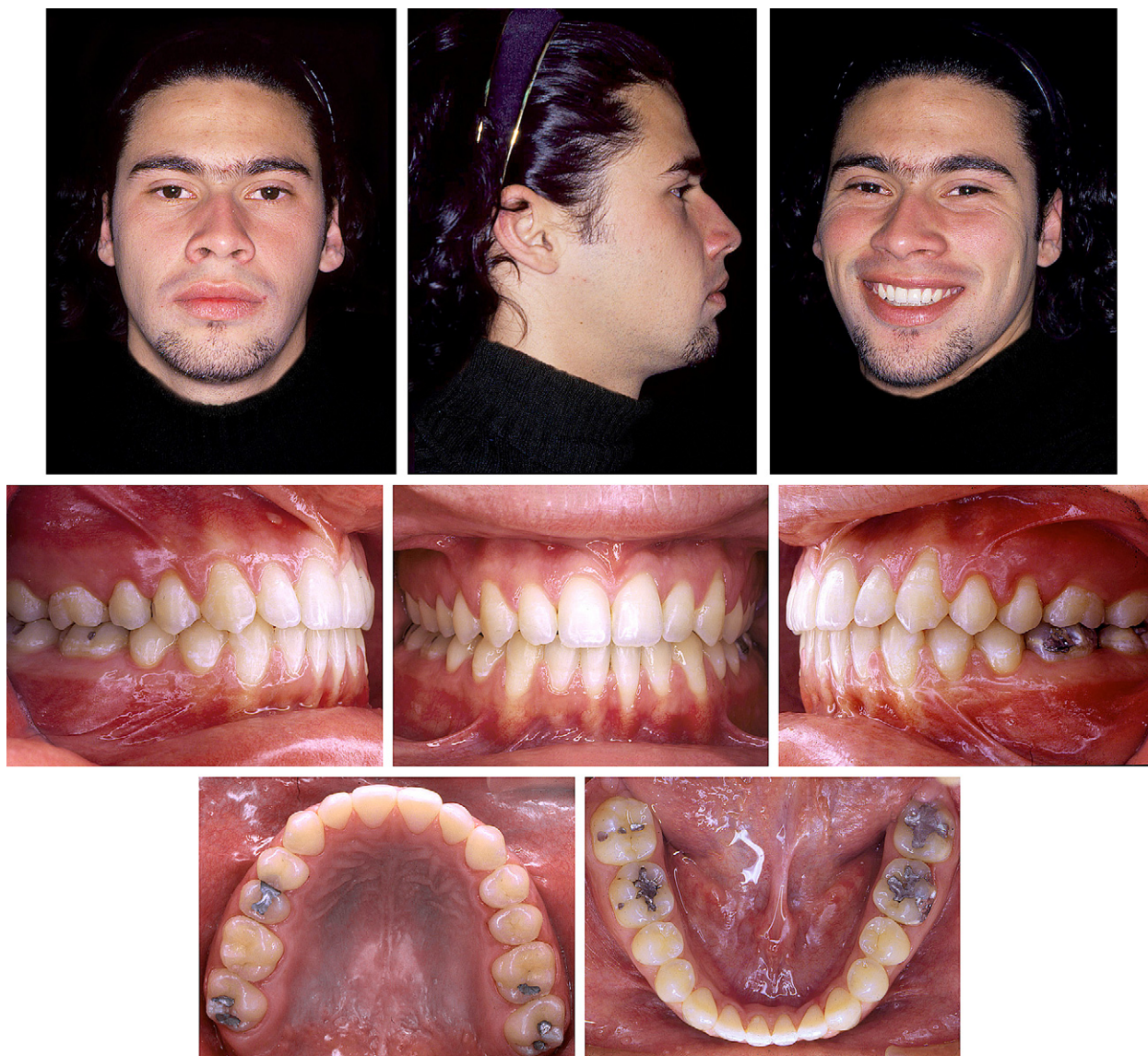At 2 years posttreatment, the occlusion appeared to be stable. The posterior interdigitation was satisfactory, and no lateral open-bite relapse was observed (Figs 10-13, Table). Maxillary retention was discontinued a year after active treatment, and mandibular retention was recommended for life. The patient has not yet had the recommended periodontal surgery.

The superimpositions of the pretreatment, posttreatment, and 2-year posttreatment lateral cephalograms and the superimposition of the maxilla showed that the maxillary incisors were retracted and extruded slightly during treatment but remained stable 2 years after treatment, with minimal relapse of tooth extrusion (Figs 14 and 15). Superimposition of the mandible showed extrusion of the mandibular incisors during treatment, with no relapse during the posttreatment period (Fig 16).

## DISCUSSION

The prevalence of lateral open bite is low. In some patients, lateral open bites are due to a disturbance of the eruption mechanism so that nonankylosed teeth cease to erupt.<sup>4</sup> Few lateral open-bite cases are reported in the literature, and all involve ankylosed teeth or primary failure of eruption.<sup>4-7</sup> We discarded the diagnosis of primary failure of eruption because the permanent molars were not involved in the open-bite problem, and the patient interposed his tongue into the open-bite space.<sup>4</sup> Thus, the etiology was considered a mechanical interference with eruption, caused by tongue thrust.

The unilateral posterior crossbite could be corrected with surgically assisted rapid maxillary expansion because the patient was an adult. Since he discarded the surgical expansion option, 2 other treatment alternatives



**Fig 6.** Posttreatment extraoral and intraoral photographs.

were analyzed. Successful maxillary expansion in non-growing patients has been questioned, because the increased convolutions of the midpalatal suture and the increased rigidity of the adjacent facial sutures do not allow for widening of the maxillary complex.<sup>15,16</sup> In addition, the tooth movement ratio to skeletal changes increases with age, and more dental tipping is expected.<sup>17</sup> Although the use of intermaxillary elastics to correct the posterior crossbite would also produce dental tipping, it was preferred because the tipping would occur only in the maxillary and mandibular left molars.

Correction of an open-bite malocclusion can be successful with conventional orthodontics. Posttreat-

ment records have shown favorable dentoalveolar changes with this therapy. Stability of treatment effects is probably the most important criterion when deciding on a treatment method for open-bite correction. A study of open-bite correction stability after nonextraction orthodontic treatment showed that 38.1% of the sample had clinically significant relapse of the open bite in the long term.<sup>18</sup> Surgical correction of open-bite malocclusion has also shown posttreatment relapse, although it was less than with nonsurgical therapy.<sup>19</sup>

Open-bite malocclusion in adults can be treated with intrusion of the maxillary and mandibular molars

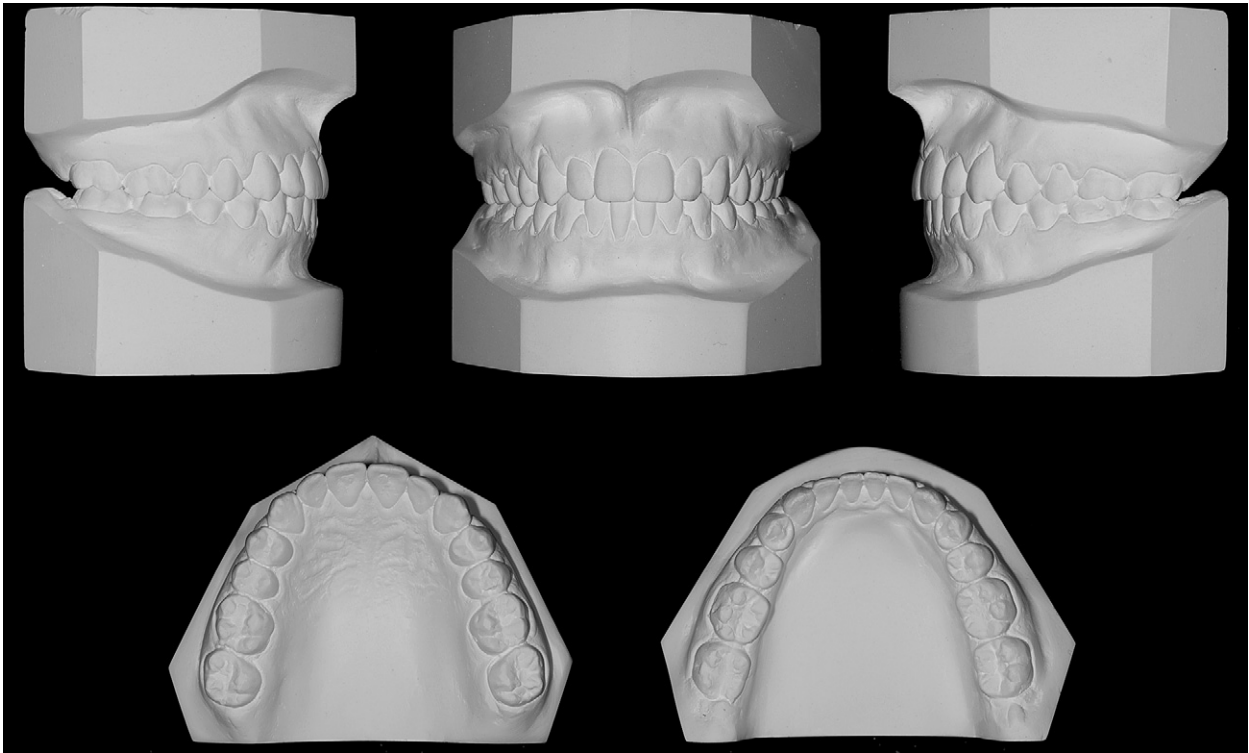


Fig 7. Posttreatment dental casts.

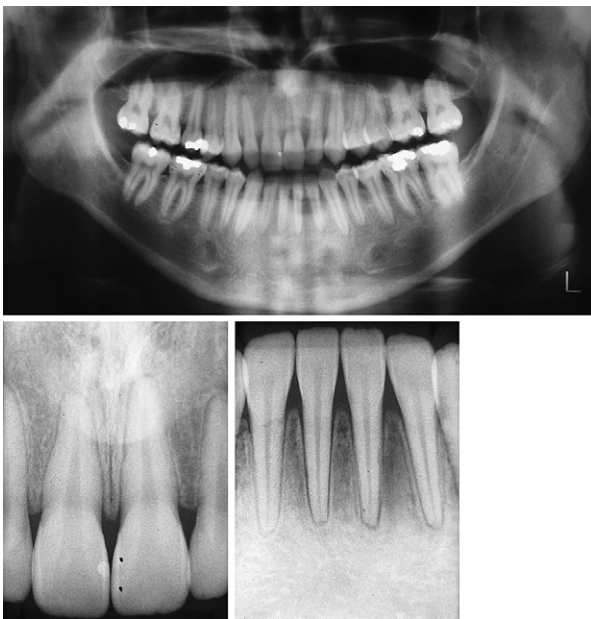


Fig 8. Posttreatment panoramic and periapical radiographs.

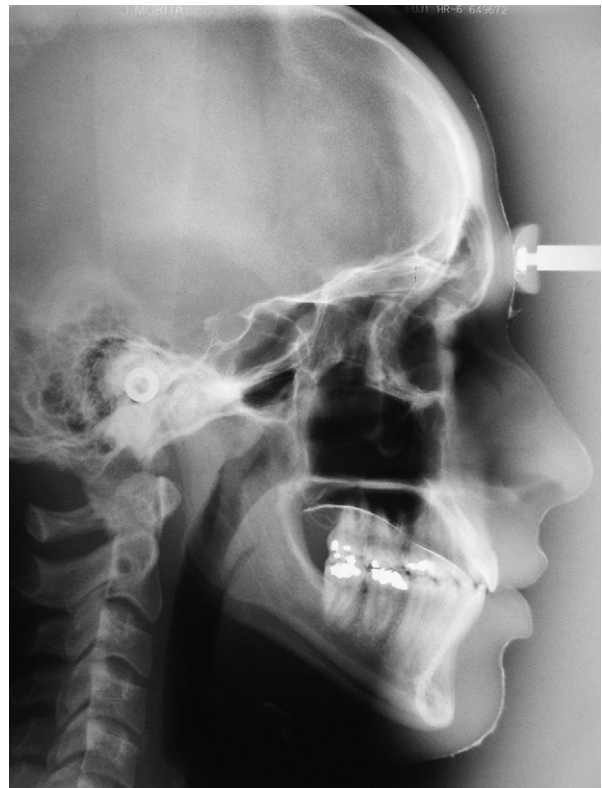
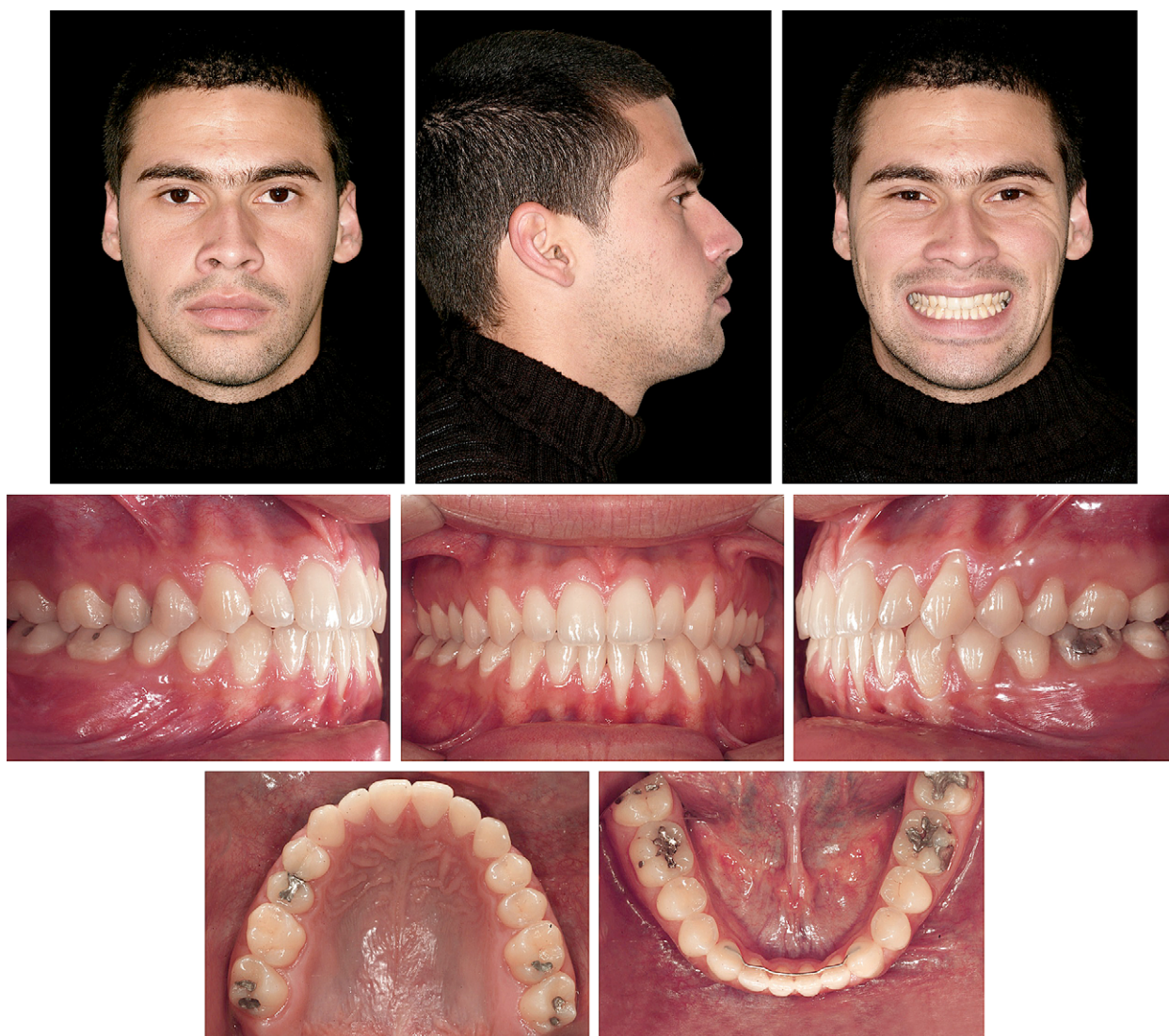

Fig 9. Posttreatment lateral cephalogram.

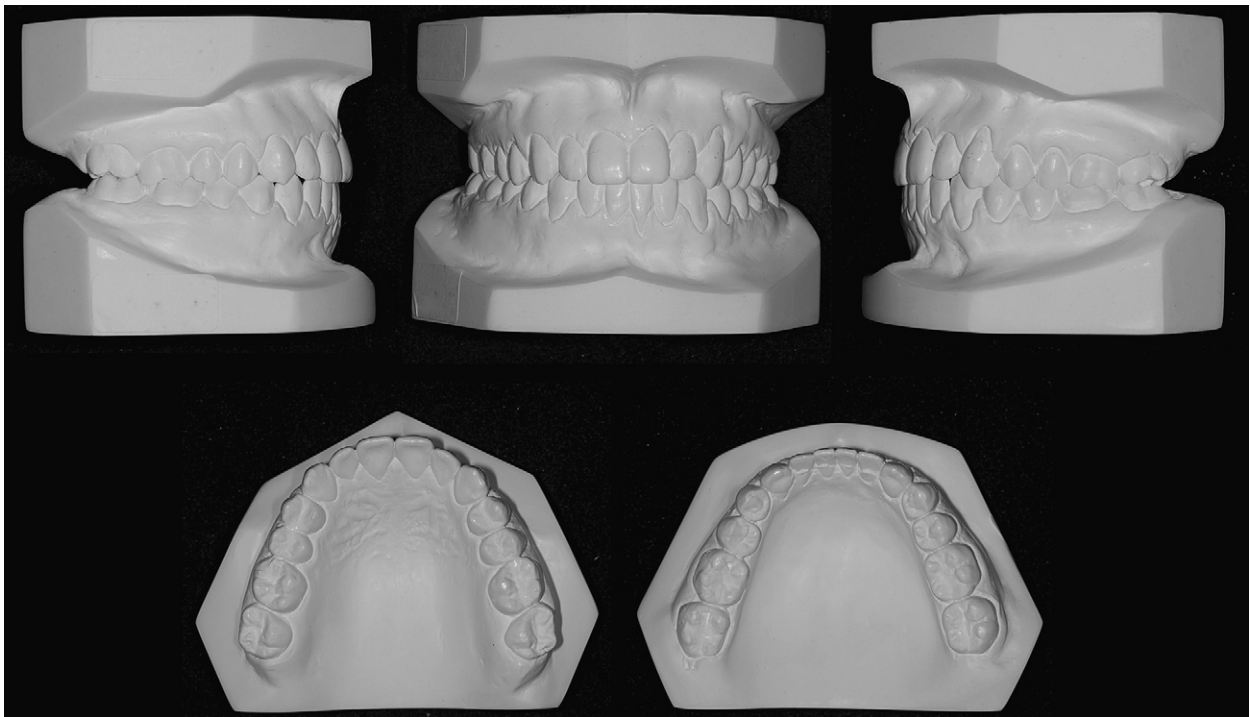


**Fig 10.** Two-year posttreatment extraoral and intraoral photographs.

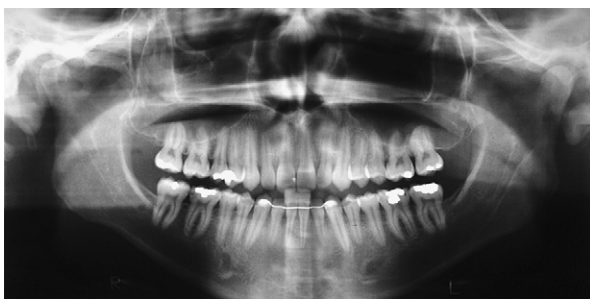by using orthognathic surgery or miniscrews, or by erupting the teeth involved in the open bite. Intrusion of the maxillary molars is usually the choice with vertical maxillary excess combined with incompetent lips.<sup>20-22</sup> Because this patient did not have a vertical growth pattern or maxillary excess, it was decided to erupt rather than to intrude the teeth. It was reported that intruded teeth are more stable than extruded teeth.<sup>23</sup> But there is still no evidence that treating open-bite patients by molar intrusion with miniscrews will provide a more stable result. Also, in patients with a habit of placing an object between their front teeth, open-bite relapse is usually the result of elongation or continuous eruption of the posterior teeth, with no apparent intrusion of the incisors.<sup>24</sup>

The use of vertical elastics to extrude the maxillary and mandibular incisors and close the open bite is a common treatment option in patients with anterior open bite, although it is contraindicated in those with skeletal open bites and maxillary incisor supereruption.<sup>25-27</sup> In our patient, the open bite was due to vertical underdevelopment of the dentoalveolar process, which is amenable to treatment with intermaxillary elastics.

On the cephalometric superimposition, it can be observed that the patient's vertical dimension was slightly increased by opening the mandibular plane angle (Fig 14). Usually, orthodontic mechanics tend to increase the vertical dimension, unless high-pull extraoral maxillary traction is used.<sup>28,29</sup> This increase is usually unstable; this would have been beneficial to this patient.<sup>30</sup>



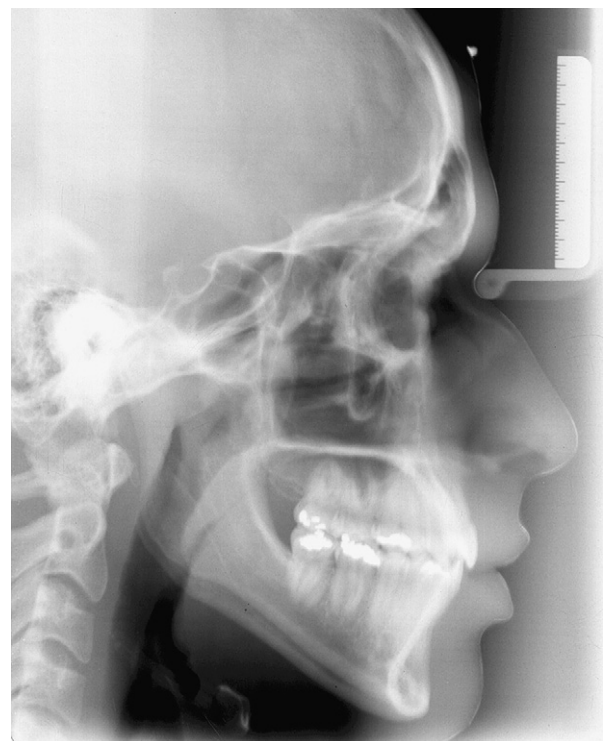**Fig 11.** Two-year posttreatment dental casts.



**Fig 12.** Two-year posttreatment panoramic radiograph.

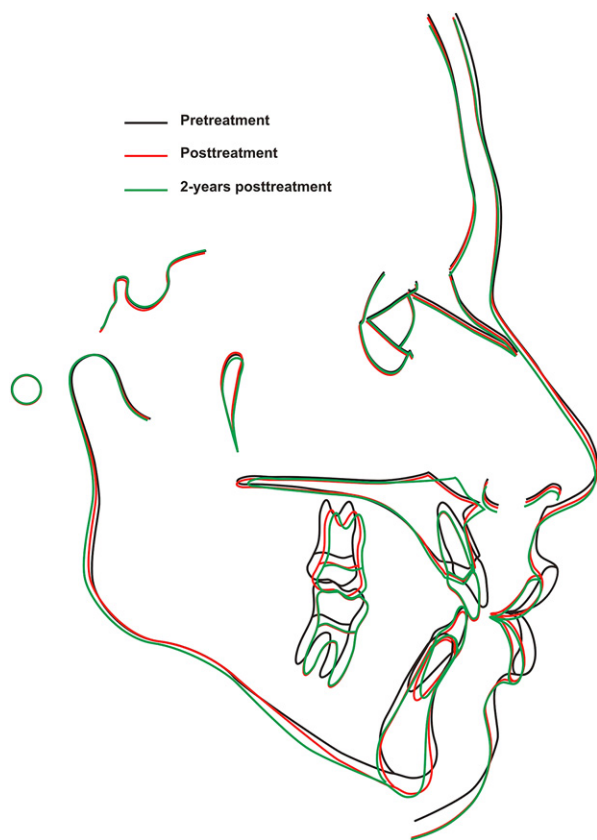
However, the follow-up headfilm and cephalometric superimposition showed that it remained stable (Figs 13 and 14). Therefore, the stability of the open-bite correction in this patient can be explained by stable tooth positioning and altered tongue function.

After treatment, the patient exhibited gingival recession of the maxillary and mandibular left canines. This recession was also present before treatment. However, no pathologic agent was causing this periodontal problem. Prophylactic management of gingival recession in at-risk orthodontic patients is a controversial issue. Widespread use of prophylactic gingival grafts to prevent recession in orthodontic patients has been reported<sup>31</sup> as well as a more cautious “watch-and-wait”

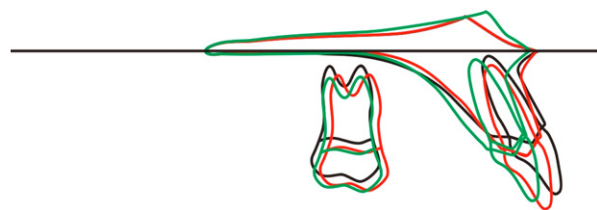


**Fig 13.** Two-year posttreatment lateral cephalogram.



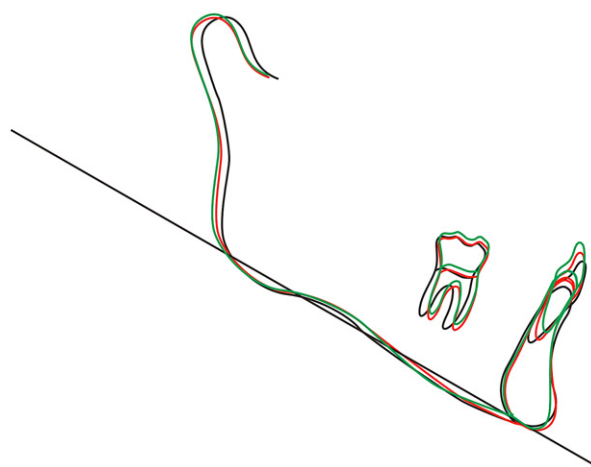


**Fig 14.** Pretreatment, posttreatment, and 2-year post-treatment cephalometric superimposition.



**Fig 15.** Pretreatment, posttreatment, and 2-year post-treatment cephalometric superimposition of the maxilla (palatal plane).

approach.<sup>32</sup> In view of the more recently documented high predictability of various surgical root coverage techniques for repairing recession defects, the latter observational philosophy seems to be appropriate for most patients.<sup>33</sup> Therefore, it was decided to perform grafts after active treatment, because the teeth would be well aligned and positioned, simplifying achievement of a correct gingival contour. After treatment, the patient was told that he should have grafts placed at these areas, but he has not yet done so. He was again advised to con-



**Fig 16.** Pretreatment, posttreatment, and 2-year post-treatment cephalometric superimposition of the mandible (mandibular plane).

**Table.** Cephalometric analysis

	<i>Pretreatment</i>	<i>Posttreatment</i>	<i>Two years posttreatment</i>
SNA	87°	89°	89°
SNB	82°	84°	85°
ANB	5°	5°	4°
SND	81°	82°	82°
Wits	-1 mm	1 mm	2 mm
NAP	8°	10°	11°
H.NB	17°	19°	17°
FMA	33°	34°	32°
SN.Occl	15°	16°	15°
SN.GoGn	35°	36°	37°
N.S.Gn	68°	68°	67°
1.NA	20°	19°	18°
1-NA	4 mm	3 mm	3 mm
1.NB	32°	25°	26°
1-NB	7 mm	8 mm	8 mm
IMPA	94°	87°	85°
P-NB	2 mm	2 mm	2 mm

sult a periodontist, because he has gingival recession on the mandibular left central incisor and the maxillary left premolars (Fig 10).

Open-bite correction is reportedly prone to relapse.<sup>11,12,18,34,35</sup> Reitan<sup>36</sup> showed that it is important to retain the teeth until the periodontal fibers have become rearranged and new bone layers have been calcified. Although the principal fibers of the periodontal ligament rearrange themselves after 8 to 9 weeks, the supra-alveolar structures behave differently and can remain stretched longer.<sup>37</sup> The supra-alveolar fibers are important for maintaining the tooth position and have a slower turnover.<sup>36,37</sup> Thus, in this patient, after

open-bite closure, the teeth were maintained in position with intermaxillary elastics for 5 months, and, when the elastics were removed, the leveling archwires were kept for an additional 5 months to decrease the likelihood of relapse.<sup>36</sup>

Another possible cause of open-bite relapse is abnormal tongue posture between the maxillary and mandibular incisors.<sup>13</sup> To minimize the open-bite relapse, the patient was referred for myofunctional therapy after orthodontic treatment, and the 2-year posttreatment evaluation showed a stable occlusion, with good stability of the lateral open-bite correction.

## CONCLUSIONS

Patients with lateral open bite caused by mechanical interference of tooth eruption and unilateral posterior crossbite can be successfully treated with fixed appliances and intermaxillary elastics. Myofunctional therapy is essential to increase the stability of the open-bite correction.

## REFERENCES

- Kukkeles N, Acar A, Demirkaya AA, Evrenol B, Enacar A. Cephalometric evaluation of open bite treatment with NiTi arch wires and anterior elastics. *Am J Orthod Dentofacial Orthop* 1999;116:555-62.
- Nielsen IL. Vertical malocclusions: etiology, development, diagnosis and some aspects of treatment. *Angle Orthod* 1991;61:247-60.
- Dung DJ, Smith RJ. Cephalometric and clinical diagnoses of open bite tendency. *Am J Orthod Dentofacial Orthop* 1988;94:484-90.
- Proffit WR, Vig KW. Primary failure of eruption: a possible cause of posterior open-bite. *Am J Orthod* 1981;80:173-90.
- Radlanski RJ, Freesmeyer WB. Bilateral open bite in dicygotic twins. A combined orthodontic-prosthetic approach. *J Orofac Orthop* 2002;63:339-47.
- Kapoor AK, Srivastava AB, Singh BP. Bilateral posterior open-bite. Abbreviated case report. *Oral Surg Oral Med Oral Pathol* 1981;51:21-2.
- Mucha JN. Treatment of a patient with unerupted mandibular molars, lateral open bite, and Class II subdivision malocclusion. *World J Orthod* 2004;5:345-56.
- Dawson PE. Evaluation, diagnosis and treatment of occlusal problems. St Louis: Mosby; 1974.
- Andrews LF. The six keys to normal occlusion. *Am J Orthod* 1972;62:296-309.
- Roth RH. Functional occlusion for the orthodontist. Part III. *J Clin Orthod* 1981;15:174-91.
- Lopez-Gavito G, Wallen TR, Little RM, Joondeph DR. Anterior open-bite malocclusion: a longitudinal 10-year postretention evaluation of orthodontically treated patients. *Am J Orthod* 1985;87:175-86.
- Kim YH, Han UK, Lim DD, Serranon ML. Stability of anterior open bite correction with multiloop edgewise archwire therapy: a cephalometric follow-up study. *Am J Orthod Dentofacial Orthop* 2000;118:43-54.
- Proffit WR, Mason RM. Myofunctional therapy for tongue-thrusting: background and recommendations. *J Am Dent Assoc* 1975;90:403-11.
- van Steenberg E, Nanda R. Biomechanics of orthodontic correction of dental asymmetries. *Am J Orthod Dentofacial Orthop* 1995;107:618-24.
- Bishara SE, Staley RN. Maxillary expansion: clinical implications. *Am J Orthod Dentofacial Orthop* 1987;91:3-14.
- Persson M, Thilander B. Palatal suture closure in man from 15 to 35 years of age. *Am J Orthod* 1977;72:42-52.
- Vanarsdall RL. Periodontal/orthodontics interrelationships. In: Graber TM, Vanarsdall RL, editors. *Orthodontics, current principles and techniques*. 2nd ed. St Louis: Mosby; 1994. p. 712-49.
- Janson G, Valarelli FP, Henriques JF, de Freitas MR, Caado RH. Stability of anterior open-bite nonextraction treatment in the permanent dentition. *Am J Orthod Dentofacial Orthop* 2003;124:265-76.
- Denison TF, Kokich VG, Shapiro PA. Stability of maxillary surgery in openbite versus nonopenbite malocclusions. *Angle Orthod* 1989;59:5-10.
- Carano A, Machata W, Siciliani G. Noncompliant treatment of skeletal open bite. *Am J Orthod Dentofacial Orthop* 2005;128:781-6.
- Subtelny J, Sakuda M. Open bite diagnosis and treatment. *Am J Orthod* 1964;50:337-58.
- Sherwood KH, Burch JG, Thompson WJ. Closing anterior open bites by intruding molars with titanium miniplate anchorage. *Am J Orthod Dentofacial Orthop* 2002;122:593-600.
- Reitan K, Rygh P. Biomechanical principles and reactions. In: Graber TM, Vanarsdall RL, editors. *Orthodontics, current principles and techniques*. 2nd ed. St Louis: Mosby; 1994. p. 168-9.
- Proffit WR, Fields HW. *Contemporary orthodontics*. St Louis: Mosby-Year Book; 1993.
- Lindsey CA, English JD. Orthodontic treatment and masticatory muscle exercises to correct a Class I open bite in an adult patient. *Am J Orthod Dentofacial Orthop* 2003;124:91-8.
- Nahoum HI. Anterior open-bite: a cephalometric analysis and suggested treatment procedures. *Am J Orthod* 1975;67:513-21.
- Cangialosi TJ. Skeletal morphologic features of anterior open bite. *Am J Orthod* 1984;85:28-36.
- Kocadereli I. The effect of first premolar extraction on vertical dimension. *Am J Orthod Dentofacial Orthop* 1999;116:41-5.
- Chua AL, Lim JY, Lubit EC. The effects of extraction versus non-extraction orthodontic treatment on the growth of the lower anterior face height. *Am J Orthod Dentofacial Orthop* 1993;104:361-8.
- Ciger S, Aksu M, Germec D. Evaluation of posttreatment changes in Class II Division 1 patients after nonextraction orthodontic treatment: cephalometric and model analysis. *Am J Orthod Dentofacial Orthop* 2005;127:219-23.
- Vanarsdall RL. Orthodontics and periodontal therapy. *Periodontol* 2000;1995(9):132-49.
- Andlin-Sobocki A, Bodin L. Dimensional alterations of the gingiva related to changes of facial/lingual tooth position in permanent anterior teeth of children. A 2-year longitudinal study. *J Clin Periodontol* 1993;20:219-24.
- Ricci G, Silvestri M, Tinti C, Rasperini G. A clinical/statistical comparison between the subpedicle connective tissue graft method and the guided tissue regeneration technique in root coverage. *Int J Periodont Restor Dent* 1996;16:538-45.

34. Janson G, Valarelli FP, Beltrão RT, de Freitas MR, Henriques JF. Stability of anterior open-bite extraction and nonextraction treatment in the permanent dentition. *Am J Orthod Dentofacial Orthop* 2006;129:768-74.
35. de Freitas MR, Beltrão RT, Janson G, Henriques JF, Cançado RH. Long-term stability of anterior open-bite extraction treatment in the permanent dentition. *Am J Orthod Dentofacial Orthop* 2004;125:78-87.
36. Reitan K. Principles of retention and avoidance of posttreatment relapse. *Am J Orthod* 1969;55:776-90.
37. Reitan K. Clinical and histologic observations on tooth movement during and after orthodontic treatment. *Am J Orthod* 1967;53:721-45.