


# Distraction Osteogenesis Maxillary Expansion (DOME) for Adult Obstructive Sleep Apnea Patients with High Arched Palate

Stanley Yung-Chuan Liu, MD, DDS<sup>1</sup>,  
 Christian Guilleminault, MD, DBiol<sup>2</sup>, Leh-Kiong Huon, MD<sup>3,4</sup>,  
 and Audrey Yoon, DDS<sup>5</sup>

Otolaryngology—  
 Head and Neck Surgery  
 1–4  
 © American Academy of  
 Otolaryngology—Head and Neck  
 Surgery Foundation 2017  
 Reprints and permission:  
 sagepub.com/journalsPermissions.nav  
 DOI: 10.1177/0194599817707168  
 http://otojournal.org  


No sponsorships or competing interests have been disclosed for this article.

## Abstract

A narrow maxilla with high arched palate characterizes a phenotype of obstructive sleep apnea (OSA) patients that is associated with increased nasal resistance and posterior tongue displacement. Current maxillary expansion techniques for adults are designed to correct dentofacial deformity. We describe distraction osteogenesis maxillary expansion (DOME) tailored to adult patients with OSA with narrow nasal floor and high arched palate without soft tissue redundancy. DOME is performed with placement of maxillary expanders secured by mini-implants along the midpalatal suture. This minimizes the maxillary osteotomies necessary to re-create sutural separation for reliable expansion at the nasal floor and palatal vault. We report the safety and efficacy profile of the first 20 patients at Stanford who underwent DOME.

## Keywords

obstructive sleep apnea, nasal obstruction, high arched palate, maxillary expansion, distraction osteogenesis, mini-implant assisted rapid maxillary expander, bone-borne maxillary expander, rapid palatal expander

Received October 26, 2016; revised March 21, 2017; accepted April 7, 2017.

A narrow maxilla with high arched palate characterizes a phenotype of patients with obstructive sleep apnea (OSA).<sup>1</sup> This is associated with increased nasal airflow resistance and posterior displacement of the tongue.<sup>2</sup> Guilleminault et al<sup>3</sup> reported a 10.9-fold increase in odds of OSA with this phenotype (**Figure 1**).

In pediatric OSA, maxillary expansion has been reported with successful long-term results.<sup>4</sup> Systematic review also reports that adults after maxillary expansion show improvement in the apnea-hypopnea index (AHI) and subjective daytime sleepiness.<sup>2</sup>

Maxillary expansion can be performed noninvasively via dental expanders prior to midpalatal suture fusion around age 15 years. Until now, adult maxilla also has been expanded with dental expanders in conjunction with surgery to re-create maxillary sutures (Lefort osteotomy and midpalatal osteotomy).

This technical note addresses 2 shortcomings with current techniques described for adult maxillary expansion, particularly in adults with OSA and narrow palate.

1. Current techniques are described for the correction of dentofacial deformity. Most patients with OSA have normal occlusion but may still present with high arched palate and narrow nasal floor.
2. Dental expanders exert force at the maxillary molars. This does not reliably expand the nasal floor along the midpalatal region, which is pertinent for patients with OSA (**Figure 2A,B**).

We describe the safety and efficacy of distraction osteogenesis maxillary expansion (DOME) for 20 patients at Stanford that addresses these shortcomings and where we convert the palatal vault from an arched to domed morphology.

<sup>1</sup>Division of Sleep Surgery, Department of Otolaryngology–Head & Neck Surgery, Stanford University School of Medicine, Stanford, California, USA

<sup>2</sup>Stanford University Sleep Medicine Division, Stanford Outpatient Medical Center, Redwood City, California, USA

<sup>3</sup>Department of Otolaryngology–Head & Neck Surgery, Cathay General Hospital, Taipei, Taiwan

<sup>4</sup>School of Medicine, Fu Jen Catholic University, Taipei, Taiwan

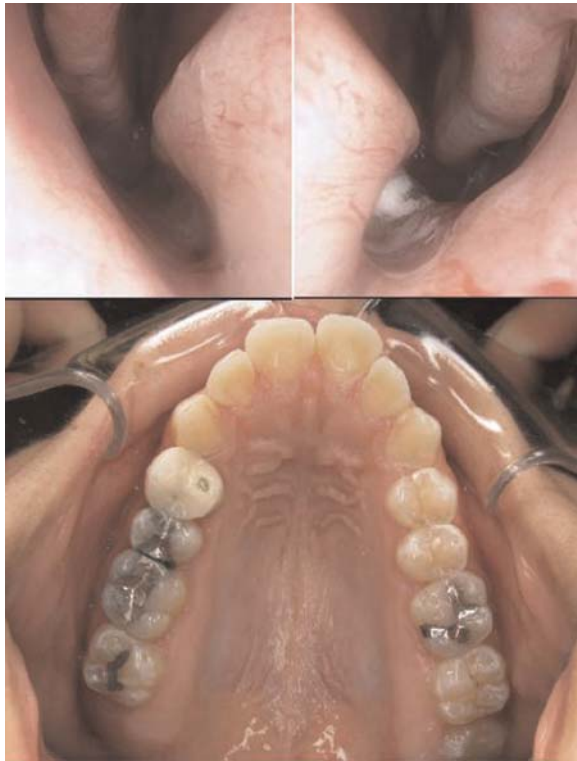<sup>5</sup>Section of Pediatric Dentistry, Division of Growth and Development, UCLA School of Dentistry, Los Angeles, California, USA

This article was presented at the 2016 AAO-HNSF Annual Meeting and OTO EXPO; September 18–21, 2016; San Diego, California.

## Corresponding Author:

Audrey Jung-Sun Yoon, DDS, Section of Pediatric Dentistry, UCLA School of Dentistry, 10833 Le Conte Ave, CHS 20-137, Los Angeles, CA 90095, USA.

Email: jungdds@gmail.com



**Figure 1.** Adult patient with obstructive sleep apnea (OSA) with maxillary morphology significant for a narrow nasal floor and high arched palate.

## Materials and Methods

### Subjects

From September 2014 to April 2016, a prospective cohort study was conducted of 20 subjects (4 women and 16 men)

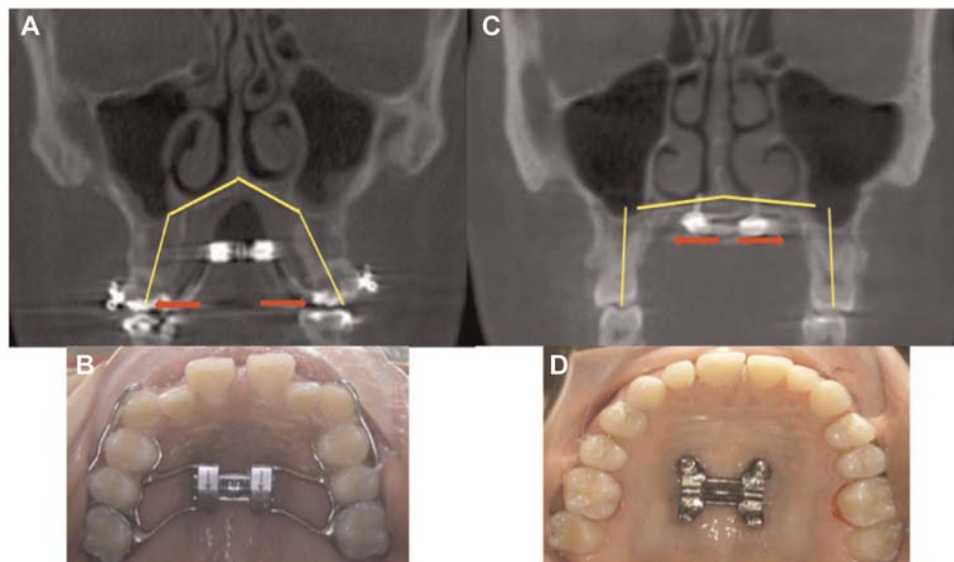
who underwent DOME after evaluation by Stanford Sleep Medicine (C.G.) and Sleep Surgery (S.Y.-C.L., A.Y.). Standard surgical consent was obtained for all subjects. This study was approved by the Institutional Review Board of Stanford University (protocol 36385, IRB 6208).

Subjects' mean age was  $31.7 \pm 6.5$  years. Patients who underwent DOME were uniformly (1) intolerant of continuous positive airway pressure (CPAP) or oral appliance therapy, (2) showed narrow palatal roof (measuring from 0.8-3 cm), (3) had no palatine or lingual tonsillar hypertrophy, and (4) were Mallampati class 4 (70%) or 3 (30%). All underwent pre- and post-DOME polysomnography (PSG) at Stanford. Outcome measures obtained include the Epworth Sleepiness Scale (ESS), Nose Obstruction Symptom Evaluation (NOSE), rhinomanometry, and computed tomography (CT) measurements of the nasal floor (**Table 1**). Paired *t* tests were used for statistical analysis with significance set at  $P < .05$ .

### DOME—Description of Techniques

**Step 1. Placement of maxillary expander with mini-implants (orthodontist).** The maxillary expander is custom-fabricated to fit the narrow palatal vault. Four to 6 mini-implants are placed along the midpalatal suture and into the maxillary bone. The orthodontist places the implant and expander in the office under local anesthesia.

**Step 2. Maxillary osteotomy (surgeon).** Two small incisions are made 1 cm above the maxillary mucogingival junction bilaterally. Lefort level I osteotomies are made. A vertical incision is made between the maxillary incisor roots. A piezoelectric saw is used to deepen the primordial groove of the midpalatal suture. Thin straight osteotomes are used to wedge open the midpalatal suture. A diastema (gap between the maxillary incisors) is seen immediately as the suture



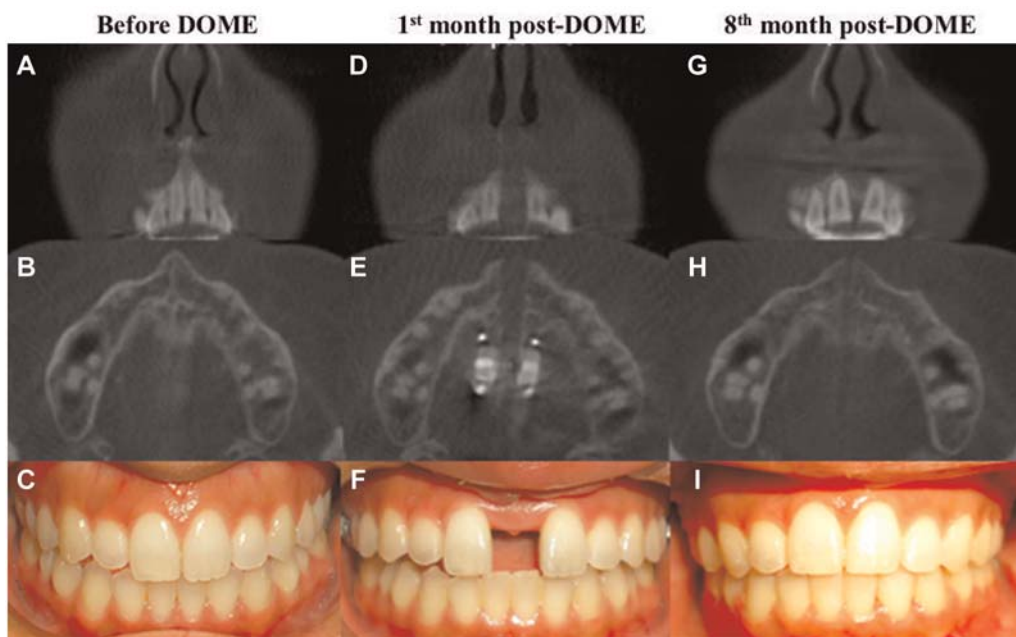
**Figure 2.** The difference in expansion force with traditional maxillary expander vs mini-implant supported expander. (**A, B**) Traditional. (**C, D**) Implant assisted. Red arrows show vector at nasal floor. Yellow line delineates maxillary anatomy.

**Table 1.** Demographic, Subjective, and Objective Parameters before and after Distraction Osteogenesis Maxillary Expansion (DOME) Procedure.<sup>a</sup>

Characteristic	Before, Mean $\pm$ SD	After, Mean $\pm$ SD	Paired <i>t</i> Test, <i>P</i> Value
BMI	26.8 $\pm$ 5.0	26.4 $\pm$ 5.5	0.44
ESS	12.3 $\pm$ 4.1	7.8 $\pm$ 4.8	<0.001
NOSE	11.7 $\pm$ 5.3	3.85 $\pm$ 3.23	<0.001
AHI	30.9 $\pm$ 27.1	14.2 $\pm$ 9.3	<0.01
ODI	23.0 $\pm$ 28.4	8.7 $\pm$ 6.9	0.07
Reff Insp (left)	1.4 $\pm$ 0.4	1.0 $\pm$ 0.5	<0.001
Reff Insp (right)	1.4 $\pm$ 0.4	0.9 $\pm$ 0.3	<0.001
Nasal floor width—anterior, mm	22.7 $\pm$ 4.58	27.4 $\pm$ 4.7	<0.001
Nasal floor width—posterior, mm	27.9 $\pm$ 4.3	32.1 $\pm$ 4.8	<0.001

AHI, apnea-hypopnea index; BMI, body mass index; ESS, Epworth Sleepiness Scale; NOSE, Nose Obstruction Symptom Evaluation; ODI, **Oxygen Desaturation Index** ; Reff Insp, effective resistance inspiration.

<sup>a</sup> Anterior nasal floor width measured at the level of nasopalatine nerve; posterior nasal floor width measured at the level of maxillary first molar palatal root.



**Figure 3.** A 24-year-old woman with obstructive sleep apnea who underwent distraction osteogenesis maxillary expansion. (A-C) Nasal floor width, palatal width, and occlusion at baseline. (D-F) One month after expansion. (G-I) Nine months after treatment (apnea-hypopnea index from 12.2 to 3.8 events/h).

opens (see Movie 1 in the online version of the article). The expander is then turned to ensure symmetric and easy separation of the maxilla bilaterally, until a 1-mm diastema is seen (see Movie 2 in the online version of the article).

**Step 3. Expansion (patient).** Patients turn the expander daily (opens by 0.25 mm). Eight to 10 mm of expansion at the nasal floor can be achieved within a month (**Figure 3**).

**Step 4. Reestablish normal occlusion (orthodontist).** Orthodontic treatment to close the gap between maxillary incisors is initiated after completion of expansion (usually 1 month after DOME surgery).

## Results

Sinus infection, oronasal fistula, loss of incisor teeth, and malunion did not occur. Minor asymmetric maxillary expansion occurred in 3 subjects but was within the range of orthodontic correction. Resolution of V<sub>2</sub> paresthesia in the anterior maxilla ranged from 1 to 6 months. Three patients Separation of the midpalatal suture and subsequent maxillary and nasal floor expansion were successfully achieved in all subjects. Significant reductions in ESS, NOSE, AHI, ODI, and nasal airflow resistance were seen. Increase of the nasal floor width at the levels of the nasopalatine nerve and first molar palatal roots was also significant (**Table 1**).

exhibited transient decrease of perfusion to the maxillary incisor with darker color change to the dentition. This resolved over the course of orthodontic treatment. Class I occlusion was achieved in all patients after expansion, with no esthetic or functional compromise.

## Discussion

We designed DOME to achieve maxillary expansion for adult patients with OSA exhibiting high arched palate and nasal obstruction. A similar phenotype in children has been well addressed with maxillary expansion.

Existing adult maxillary expansion techniques, however, are directed mainly for treating expansion dentofacial deformity. Frequent called SARPE (surgery-assisted rapid palatal expansion), it has the shortcoming of using dental expanders that require invasive osteotomy, including pterygoid plate fracture that carries significant bleeding risk. Furthermore, forces exerted at the dentition do not reliably lead to expansion of bone at the midpalatal junction, leading to a relapse rate as high as 64%.<sup>5</sup>

With mini-implants, DOME negates the need to perform pterygoid disjunction. Furthermore, the force is exerted at the height of palatal vault and nasal floor. It is readily applied to patients with normal, albeit narrow, jaw occlusal relationship. Results need to be interpreted with the fact that expanders remain in place for at least 8 months after distraction osteogenesis, and we do not have data on long-term relapse at this time.

## Conclusion

DOME is conceived to widen the maxilla of adult patients with OSA with high arched palate and normal occlusion. It requires minimal maxillary osteotomies to reliably expand the adult maxilla. The reduction in objective and subjective measures of OSA in this patient phenotype requires long-term follow-up to establish DOME as a form of “skeletal” palate surgery.

## Author Contributions

**Stanley Yung-Chuan Liu**, original conception, design, analysis and drafting the work, total clinical treatment and writing the

manuscript; **Christian Guilleminault**, data analysis, interpretation of data, revising the work; **Leh-Kiong Huon**, acquisition of data and revising the work; **Audrey Yoon**, original conception, design, analysis and drafting the work, total clinical treatment and reviewing the manuscript.

## Disclosures

**Competing interests:** None.

**Sponsorships:** None.

**Funding source:** None.

## Supplemental Material

Additional supporting information is available in the online version of the article.

## References

1. Johal A, Conaghan C. Maxillary morphology in obstructive sleep apnea: a cephalometric and model study. *Angle Orthod.* 2004;74:648-656.
2. Abdullatif J, Certal V, Zaghi S, et al. Maxillary expansion and maxillomandibular expansion for adult OSA: a systematic review and meta-analysis. *J Craniomaxillofac Surg.* 2016;44:574-578.
3. Guilleminault C, Partinen M, Hollman K, et al. Familial aggregates in obstructive sleep apnea syndrome. *Chest.* 1995;107:1545-1551.
4. Pirelli P, Saponara M, Guilleminault C. Rapid maxillary expansion (RME) for pediatric obstructive sleep apnea: a 12-year follow-up. *Sleep Med.* 2015;16:933-935.
5. Chamberland S, Proffit WR. Short-term and long-term stability of surgically assisted rapid palatal expansion revisited. *Am J Orthod Dentofacial Orthop.* 2011;139:815-822.