

See discussions, stats, and author profiles for this publication at: <https://www.researchgate.net/publication/287376983>

An interdisciplinary study of orthodontic, orthopedic, and otorhinolaryngological findings in 12-14-year-old preorthodontic children

Article · January 2013

CITATIONS

2

READS

6

6 authors, including:



[Dalia Smaliene](#)

Lithuanian University of Health Sciences

19 PUBLICATIONS 94 CITATIONS

[SEE PROFILE](#)



[Monika Šidlauskienė](#)

Lithuanian University of Health Sciences

6 PUBLICATIONS 9 CITATIONS

[SEE PROFILE](#)



[Ruta Pribuisiene](#)

Lithuanian University of Health Sciences

20 PUBLICATIONS 169 CITATIONS

[SEE PROFILE](#)

Some of the authors of this publication are also working on these related projects:



palatally impacted canines [View project](#)



voice and speech disorders screening [View project](#)

An Interdisciplinary Study of Orthodontic, Orthopedic, and Otorhinolaryngological Findings in 12–14-Year-Old Preorthodontic Children

Kristina Lopatienė¹, Dalia Smailienė¹, Monika Šidlauskienė¹, Emilis Čekanauskas², Raimonda Valaikaitė², Rūta Pribuišienė³

¹Department of Orthodontics, Medical Academy, Lithuanian University of Health Sciences,

²Department of Orthopedics and Traumatology, Medical Academy, Lithuanian University of Health Sciences,

³Department of Otorhinolaryngology, Medical Academy, Lithuanian University of Health Sciences, Lithuania

Key Words: malocclusion; body posture; breathing pattern.

Summary. *Background and Objective.* Malocclusion, the body posture, and the breathing pattern may correlate, but this issue is still controversial. The aim of the study was to examine the relationship between the type of malocclusion, the body posture, and the nasopharyngeal obstruction in 12–14-year-old children.

Material and Methods. The study group consisted of 76 orthodontic patients (35 boys, 41 girls) aged 12–14 years (mean age, 12.79 years [SD, 0.98]). All the patients were examined by the same orthodontist (study model and cephalometric radiograph analysis), the same orthopedic surgeon (body posture examined from the front, the side, and the back), and the same otorhinolaryngologist (anterior and posterior rhinoscopy and pharyngoscopy) in a blind manner.

Results. The prevalence of a poor body posture and a nasopharyngeal pathology was high in the present study. In total, 48.7% of the orthodontic patients had a kyphotic posture and 55.3% a rib hump in the thoracic region. The nasopharyngeal pathology was diagnosed in 78.9% of the patients. The patients with the kyphotic posture had a higher mandibular plane angle (MP–SN) and a lower sagittal position of the mandible SNB angle. A deeper overbite correlated with shoulder and scapular asymmetry. The kyphotic posture was diagnosed in 55.0% of the patients with the nasopharyngeal pathology.

Conclusions. The sagittal body posture was related to the vertical craniofacial parameters and hypertrophy of the tonsils and/or the adenoids. The study showed no relationship between the degree of crowding, the presence of a posterior cross bite, orthopedic parameters, and a breathing pattern.

Introduction

The posture of the human body is the result of many types of inputs of sensory information arising from the visual, the vestibular, and the proprioceptive systems, integrated in the complex regulatory system. A poor body posture is primarily a muscular problem. It depends on the body build, general health, sex, psychological state, strength and endurance, demands of the work place, and social as well as cultural traditions. According to literature, the poor posture is mostly influenced by the muscular problem; children who have no sport activities have a significantly higher probability of the poor posture than children performing sports (1, 2). Changes of our modern way of life influence our body structure and posture at work or rest that demand prolonged sitting or prolonged standing with resultant muscular fatigue and inability to sustain adequate support. In the last century, Wachsmann stated that muscular

weakness, which is considered to be related to the weakness of the mesoderm, might be the cause of mouth breathing, prognathism, and a flabby body posture. The stomatognathic system plays an important role in postural control, and reciprocally, dental occlusion may be influenced by postural pathologies (3–9). In a finite element study, Motoyoshi et al. found that alterations of the occlusion affected the head posture, whereas a change of the head posture did not always directly influence occlusion (10). Malocclusion, the body posture, and the breathing pattern may correlate, but this issue is still controversial. Every year, with a major surge since 2000, new investigations are carried out, and new results about the correlation between the body posture and dental occlusion emerge (11).

Most recent studies concentrate on the relationship between malocclusion and the head posture (12–14) or on the morphology of the cervical vertebrae (15–18). Solow and Sandham stated that flexion of the head was associated with a more pronounced forward growth rotation of the mandible, increased mandibular prognathism, and a small anterior face height, whereas extension of the head

Correspondence to K. Lopatienė, Department of Orthodontics, Medical Academy, Lithuanian University of Health Sciences, J. Lukšos-Daumanto 6, 50106 Kaunas, Lithuania
E-mail: klopatiene@zebra.lt

was accompanied by a large anterior face height, backward rotation of the mandible, and maxillary and mandibular retrognathism (19).

Another group of studies evaluated the relation between the whole body posture and malocclusion (20–24). It is evident that structural orthopedic diseases are associated with occlusal morphology (20, 25–28). However, there are still controversial results from available studies about the correlation between the poor body posture and dental occlusion. Perrillo et al. did not find any evidence of clinical associations between the body posture and dental occlusion either in the sagittal or transverse dimensions (24).

Nasopharyngeal pathology causes mouth breathing and affects the postural change. An altered respiration pattern implies necessary adaptive body postures (29). There is a consensus that anterior tilting of the head is the main change. Such individuals anteriorize their heads and extend their necks to facilitate airflow through the mouth. This adaptation results in muscle imbalance and alters the posture. Previous studies have reported both significant and nonsignificant correlations between the body posture and the breathing pattern (29–33).

After evaluating the contradictory results of the previous studies, a decision was made to evaluate the correlation between malocclusion and the orthopedic and the nasopharyngeal pathology in growing patients. Therefore, the aim of this study was to examine the relationship between the type of malocclusion, the body posture, and the nasopharyngeal obstruction in 12–14-year-old children.

Material and Methods

The study was carried out in the Departments of Orthodontics, Orthopedic Traumatology, and Otolaryngology, Medical Academy, the Lithuanian University of Health Sciences, Kaunas, Lithuania. The sample was obtained by approaching consecutive patients who agreed to participate in the study, attending for orthodontic treatment in the Department of Orthodontics. The parents of all the patients were informed about the study and signed a consent form after a full explanation of the aims and the procedures of the study. An approval for the study was obtained from Kaunas Regional Biomedical Research Ethics Committee (No. BE-2-48).

The study group consisted of 76 patients aged 12–14 years (mean age, 12.79 years [SD, 0.98]). There were 35 boys (46.1%) and 41 girls (53.9%). All the patients were examined by the same orthodontist, the same orthopedic surgeon, and the same otorhinolaryngologist in a blind manner.

The main criteria for including the patients into the study group were as follows: age 12–14 years; no previous maxillofacial trauma or surgery, syndromes, clefts, or orthodontic treatment; no previous treatment of orthopedic disorders of the mus-

culoskeletal system and no previous injuries to the pelvis, spine, or the long bones of the legs; and no structural orthopedic diseases.

Orthodontic Examination. The orthodontic examination consisted of the study model analysis and the cephalometric radiograph analysis. The study model examination consisted of the sagittal examination, where overjet (OJ) was evaluated as normal (1–3 mm), increased (>3 mm), and decreased (<1 mm), the transverse examination where the posterior cross bite was confirmed when at least 1 tooth was in a cross relationship with 1 or more of the opposite teeth, and the vertical examination, where overbite (OB) was evaluated as normal (1–3 mm), increased (>3 mm), and decreased (<1 mm). Space analysis was calculated as the difference between the available space and the necessary space. Crowding was evaluated as mild (lack of space 2–4 mm), moderate (5–9 mm), or severe (>9 mm) (34).

Lateral cephalometric radiographs were analyzed using the Dolphin software (version 10.5). The sagittal position of the maxilla (SNA) and the mandible (SNB), the sagittal jaw relationship (ANB), the mandibular plane angle (MP-SN), and maxillary incisors and mandibular incisors inclination (U1-NA and L1-NB, respectively) were used for the analysis of the facial skull. The width of the upper airway (UA) was measured as the distance from the point of the posterior outline of the soft palate to the closest point on the posterior pharyngeal wall. The width of the lower airway (LA) was measured as the distance from the intersection of the posterior border of the tongue and the inferior border of the mandible to the closest point on the posterior pharyngeal wall (35). The parameters used for this study are shown in Fig. 1.

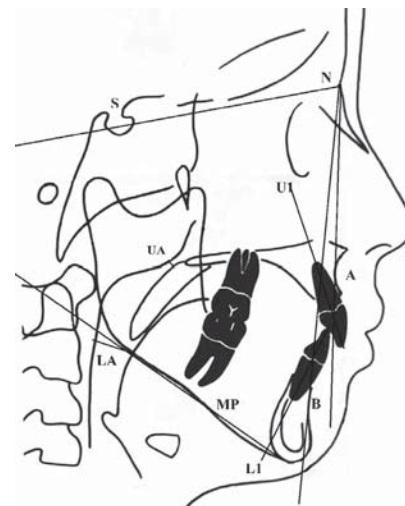


Fig. 1. Reference points and lines used for this study

The sagittal position of the maxilla (SNA) and the mandible (SNB), sagittal jaw relationship (ANB), the mandibular plane angle (MP-SN), inclination of the maxillary incisors and the mandibular incisors (U1-NA and L1-NB, respectively), the width of the upper airway (UA), and the width of the lower airway (LA).

For models and the lateral cephalometric analysis, the error margin was determined by repeating the measurements of 6 variables on randomly selected 10 models and radiographs at 2-week intervals with the same operator; the paired sample *t* test showed no significant mean differences in the 2 data sets.

Orthopedic Examination. The patients were examined from the front, the side, and the back (Fig. 2). From the side, thoracic kyphosis was evaluated (2). If an increased but adjustable asymptomatic thoracic spine curve was observed, the pathology was considered as a kyphotic posture. All the patients underwent testing to rule out Scheuermann's disease and ankylosing spondylitis. The patients were asked to stand upright and brace back the shoulders to produce extension. In cases of postural kyphosis, an increased curvature, which is regular and

mobile, was found. From the front, the position of the shoulders, the symmetry of the waist triangles, and the horizontality of the frontal upper iliac crests were examined. From the back, the position of the shoulders, the scapular height, the symmetry of the waist triangles, the iliac crests, and the thoracic rib hump were evaluated. All the patients underwent testing to rule out scoliosis.

Otorhinolaryngological Examination. Anterior and posterior rhinoscopy and pharyngoscopy were performed to assess the nasal and the pharyngeal status. According to the findings of this examination, the following diagnoses were made: grade 2–3 hypertrophy of the adenoids, when up to two-thirds of the choana were compromised (36); grade 2–4 hypertrophy of the palatal tonsils, when there was <50% of the space between tonsillar pillars (37); the

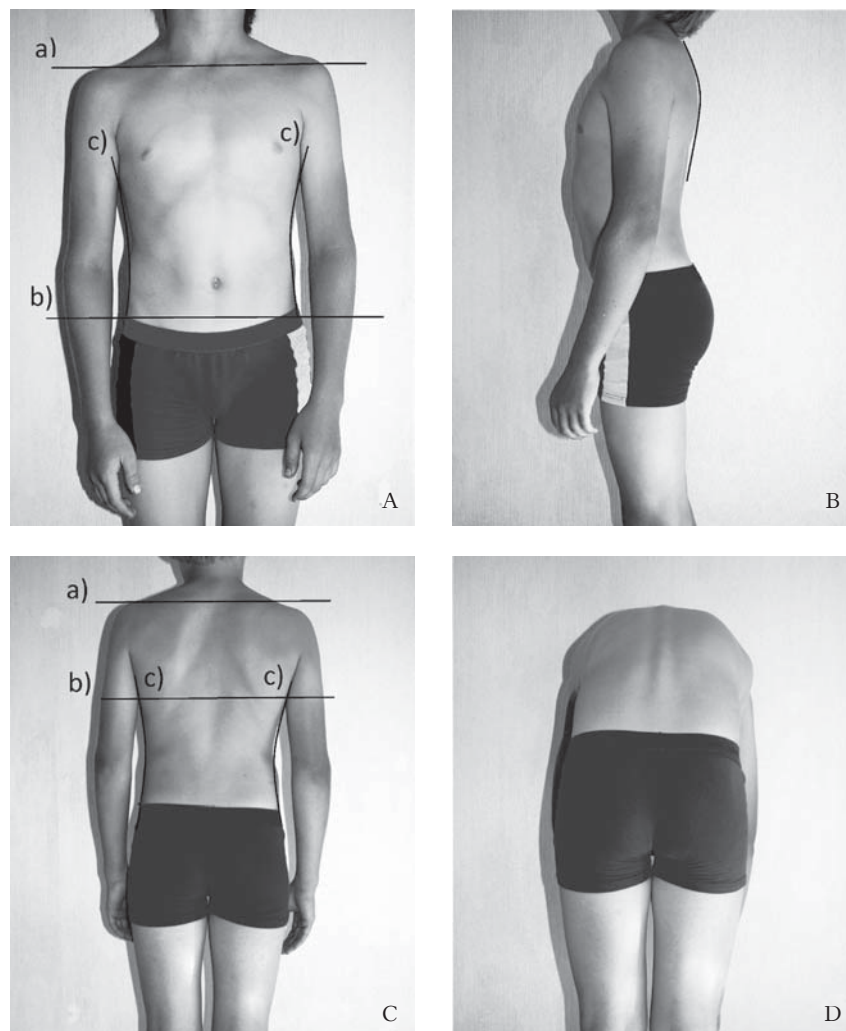


Fig. 2. Orthopedic examination

A, the evaluation from the front: a) symmetry of the shoulders; b) symmetry of the waist triangles; c) horizontality of the frontal upper iliac crests. B, thoracic kyphosis has to be evaluated from the side. C, the evaluation from the back: a) symmetry of the shoulders; b) the scapular height; c) symmetry of the waist triangles. D, a test to confirm or deny scoliosis. It has to be observed if the paravertebral muscle roller emerges in the lumbar region and the rib hump in the thoracic region.

nasal septum deviation, when the failure of the nasal septum in the center was detected; allergic rhinitis, when typical allergy symptoms (nasal congestion, runny nose, sneezing, and watery eyes) were detected and the allergologist's confirmation based on the results of the skin prick test was obtained.

The statistical analysis was performed using the statistical software package SPSS 20.0 for Windows. The *t* test, χ^2 test, and one-way ANOVA test regression analysis were applied to evaluate the association between the orthodontic, the orthopedic, and the nasopharyngeal pathology. The difference was considered statistically significant when $P < 0.05$.

Results

Malocclusion Evaluation. A normal overjet was found in 28 patients (36.8%), increased in 43 patients (56.6%), and decreased in 5 patients (6.6%). A normal overbite was found in 19 patients (25.0%), increased in 56 patients (73.7%), and decreased in 1 patient (1.3%). A posterior cross bite was found in 14 patients (18.4%). According to space analysis, crowding was documented in 57 patients (75%) (mild crowding in 32.9%, moderate in 34.2%, and severe in 7.9%) and spacing in 5 patients (6.6%).

The findings of the orthopedic examination were as follows: among the orthopedic anomalies, the kyphotic posture (37 patients, 48.7%) and the rib hump in the thoracic region (42 patients, 55.3%) were prevalent. The asymmetric position of the shoulder line was detected in 21 patients (27.6%), the scapular asymmetry in 21 (27.6%), and the asymmetry of the waist triangles in 5 patients (6.6%).

The results of the otorhinolaryngological examination were as follows: 1 or more nasopharyngeal pathologies (hypertrophy of the adenoids, hypertrophy of the tonsils, the deviation of the nasal septum, or allergic rhinitis) were diagnosed in 60 patients (78.9%). The hypertrophy of the adenoids was diagnosed in 22 patients (28.9%): grade 2 in 13 patients (17.1%) and grade 3 in 9 patients (11.8%). The hypertrophy of the tonsils was found in 29 patients (38.2%): grade 2 in 11 patients (14.5%), grade 3

in 12 patients (15.8%), and grade 4 in 6 patients (7.9%). In addition, 11 patients (14.5%) had previously undergone adenoidectomy and 3 patients (3.9%) tonsillectomy. The deviation of the nasal septum was recorded in 45 patients (59.2%), and allergic rhinitis was diagnosed in 14 patients (18.4%).

When evaluating the relationship between the orthodontic and the sagittal orthopedic pathology, a significant correlation between the angles SNB and MP-SN and thoracic kyphosis was found, $P < 0.05$ (Table 1).

The evaluation of the relationship between the orthodontic and the transversal orthopedic pathology (Table 2) demonstrated a correlation between the degree of the overbite and the symmetry of the shoulder line and the position of the scapulae, $P < 0.05$. The deeper overbite correlated with the shoulder and the scapular asymmetry. No relationship between crowding, the posterior cross bite, and the sagittal or the transversal orthopedic parameters was found.

In the study, the relationship between the orthodontic pathology and the hypertrophy of the tonsils or/and the adenoids was evaluated. A statistically significant correlation between the increased MP-SN angle, the decreased width of the upper pharynx, and the hypertrophy of the tonsils or/and the adenoids was found ($P < 0.05$) (Table 3). No relationship between crowding, the posterior cross bite, or the hypertrophy of the tonsils or/and the adenoids was found.

The evaluation of the relationship between the nasopharyngeal pathology and the sagittal orthopedic pathology showed that thoracic kyphosis was more common among the patients with the nasopharyngeal pathology. The kyphotic posture was diagnosed in 33 patients (55.0%) with the nasopharyngeal pathology and only in 4 patients (25.0%) without such a pathology ($P = 0.033$).

There was no correlation between the nasopharyngeal pathology and the transversal orthopedic pathology. A statistically significant correlation was found between the presence of more than

Table 1. Relationship Between Orthodontic Variables and Sagittal Orthopedic Parameters

Orthodontic Variable	Sagittal Orthopedic Parameter (Thoracic Kyphosis)				P
	Normal Thoracic Kyphosis (N=39)		Kyphotic Posture (N=37)		
	Mean	SD	Mean	SD	
Sagittal position of the maxilla, SNA°	82.18	3.75	81.17	3.14	0.20
Sagittal position of the mandible, SNB°	78.95	4.08	76.61	3.50	0.01
Sagittal jaw relationship, ANB°	3.24	2.89	4.41	2.89	0.08
Mandibular plane angle, MP-SN°	31.76	5.78	34.81	5.37	0.02
Inclination of maxillary incisors, U1-NA°	23.19	8.61	21.80	8.27	0.47
Inclination of mandibular incisors, L1-NB°	23.18	7.07	24.19	6.93	0.53
Overjet, mm	3.58	2.80	4.68	2.89	0.94
Overbite, mm	4.05	1.78	4.86	2.22	0.32
Width of upper airway, mm	15.56	2.49	15.38	1.90	0.717
Width of lower airway, mm	11.38	2.03	12.08	2.17	0.152

1 pathology (the hypertrophy of the adenoids, the hypertrophy of the tonsils, the nasal septum deviation, allergic rhinitis, or thoracic kyphosis) and the increased MP-SN angle, the decreased SNB angle, and the increased width of the lower airway, $P < 0.05$ (Table 4).

Discussion

The present study was based on the assumption that the type of malocclusion, the body posture, and the breathing pattern were interdependent.

The study group consisted of 12–14-year-old orthodontic patients. Such age of the patients was selected on the basis of growth peculiarities. A healthy child at around 7 years of age assumes a normal shape of the spine with physiological lordosis in the cervical and the lumbar areas and physiological kyphosis curves in the thoracic area. The spine grows unevenly, i.e., the longitudinal rate of the growth of the spine is not constant: there is a period of accelerated growth, which occurs at the age between 10.5 and 15.5 years (38), and the peak height velocity averages at an age of 12.2 years in girls and 13.9 years in boys (39). During the peak growth of the spine, the intensive growth of the vertebrae occurs, while the growth of the muscles and the ligaments lags by ~1–2 years. Therefore, during this period, the muscle growth and the strength are insufficient, and the shoulder–scapular asymmetry is a normal phenomenon. After the end of the growth spurt, postural defects often disappear spontaneously.

There was a high prevalence of the orthopedic anomalies in the study group. Less than half (48.7%) of the orthodontic patients had kyphotic postures. A study by Lippold et al. revealed orthopedic pathological findings in 52% of preschool children (3.5–6.8 years) (20). The prevalence of the nasopharyngeal pathology was also very high in the present study, i.e., it was diagnosed in 78.9% of the patients. According to literature, the prevalence of the hypertrophy of the adenoids and the tonsils – which causes mouth breathing – is high among children, i.e., it varies from 40% to 60% (40, 41).

The evaluation of the results of the study showed that the sagittal body posture was related to the vertical craniofacial parameters. The patients with the kyphotic posture had higher MP-SN angles and lower SNB angles, which, of course, was related to the backward rotation of the mandible because of the increasing facial height. According to our results, an increase in the MP-SN angle also significantly correlated with the hypertrophy of the tonsils and/or the adenoids. The evaluation of the relationship between the nasopharyngeal pathology and the sagittal orthopedic pathology showed that thoracic kyphosis was more common among the patients with the nasopharyngeal pathology. The ANOVA

Table 2. Correlations between Orthodontic Variables and Transversal Orthopedic Parameters

Orthodontic Variable	Transversal Orthopedic Parameter																			
	Symmetry of the Shoulder Line			Position of Scapulae			Waist Triangles			Rib Hump in Thoracic Region										
	Symmetry (N=55)	Asymmetry (N=21)	P	Symmetry (N=55)	Asymmetry (N=21)	P	Symmetry (N=71)	Asymmetry (N=5)	P	Absent (N=34)	Present (N=42)	P								
Mean	SD	Mean	SD	Mean	SD	Mean	SD	Mean	SD	Mean	SD	Mean	SD							
Sagittal position of the maxilla, SNA°	81.3	3.07	82.7	4.01	0.10	81.48	3.03	82.24	4.23	0.39	81.79	3.46	80.2	1.63	0.31	81.72	3.47	81.67	3.36	0.95
Sagittal position of the mandible, SNB°	77.28	3.70	79.19	4.39	0.06	77.76	3.92	77.91	4.16	0.88	77.79	4.04	78.00	2.92	0.91	77.44	3.76	78.1	4.13	0.47
Sagittal jaw relationship, ANB°	3.92	30.6	3.5	2.58	0.58	3.61	3.14	4.33	2.25	0.34	3.9	2.96	2.48	2.27	0.30	4.16	2.82	3.52	3.01	0.35
Mandibular plane angle, MP-SN°	34	5.15	31.27	6.86	0.06	33.59	5.79	32.35	5.72	0.41	33.52	5.51	29.3	8.30	0.11	33.72	5.34	32.85	6.11	0.51
Inclination of maxillary incisors, UI-NA°	22.67	8.92	22.07	7.11	0.78	21.86	8.07	14.3	5.45	0.28	22.45	8.38	23.40	9.94	0.81	20.89	6.49	23.82	9.59	0.13
Inclination of mandibular incisors, L1-NB°	23.79	6.91	23.38	7.29	0.82	23.47	6.95	24.21	7.18	0.68	23.91	6.87	20.32	8.19	0.27	23.85	7.33	23.53	6.76	0.84
Overjet, mm	4.28	3.00	21	3.67	0.41	3.92	3.11	4.59	2.22	0.37	4.15	2.93	2.5	2.44	0.63	3.87	2.37	4.31	3.28	0.51
Overbite, mm	4.32	1.96	5.42	1.98	0.03	4.36	1.95	5.39	2.07	0.05	4.61	2.07	4.80	0.45	0.85	4.318	1.82	4.88	2.14	0.23
Width of upper airway, mm	15.45	2.12	15.52	2.31	0.90	15.2	2.05	16.19	2.50	0.08	15.42	2.25	16.2	1.64	0.45	14.85	2.21	15.98	2.10	0.03
Width of lower airway, mm	11.75	1.89	11.67	2.67	0.89	11.58	2.23	12.10	1.76	0.35	11.73	1.96	11.6	4.03	0.89	11.47	1.76	11.93	2.36	0.34

Table 3. Relationship Between Orthodontic Variables and Hypertrophy of Adenoids or/and Tonsils

Orthodontic Variable	Condition of Adenoids or Tonsils				P
	No Hypertrophy (N=34)		With Hypertrophy (N=42)		
	Mean	SD	Mean	SD	
Sagittal position of the maxilla, SNA°	81.53	3.78	81.82	3.07	0.36
Sagittal position of the mandible, SNB°	77.69	3.84	77.90	4.09	0.40
Sagittal jaw relationship, ANB°	3.76	2.41	3.84	3.316	0.45
Mandibular plane angle, MP-SN°	31.91	4.90	34.32	6.21	0.03
Inclination of maxillary incisors, U1-NA°	22.80	9.56	22.27	7.47	0.39
Inclination of mandibular incisors, L1-NB°	24.30	7.38	23.17	6.67	0.24
Overjet, mm	4.66	2.92	3.66	2.82	0.06
Overbite, mm	4.48	1.90	4.74	2.10	0.28
Width of upper airway, mm	16.09	2.03	14.98	2.24	0.01
Width of lower airway, mm	11.47	2.24	11.93	2.00	0.17

Table 4. Relationship Between Hypertrophy of Adenoids, Hypertrophy of Tonsils, Nasal Septum Deviation, Allergic Rhinitis, Thoracic Kyphosis, and Orthodontic Variables

Orthodontic Variable	Presence of Hypertrophy of Adenoids, Hypertrophy of Tonsils, Nasal Septum Deviation, Chronic Allergic Rhinitis, and/or Thoracic Kyphosis				P
	1 or no Pathology (N=52)		More than 1 Pathology (N=24)		
	Mean	SD	Mean	SD	
Sagittal position of the maxilla, SNA°	81.94	3.48	81.14	3.15	0.17
Sagittal position of the mandible, SNB°	78.37	3.95	76.58	3.77	0.03
Sagittal jaw relationship, ANB°	3.51	2.69	4.45	3.34	0.09
Mandibular plane angle, MP-SN°	31.80	5.26	36.37	3.57	0.0005
Inclination of maxillary incisors, U1-NA°	22.85	8.87	21.77	7.45	0.30
Inclination of mandibular incisors, L1-NB°	23.48	7.48	24.08	5.83	0.36
Overjet, mm	3.97	2.88	4.41	2.96	0.29
Overbite, mm	4.46	1.85	4.97	2.31	0.152
Width of upper airway, mm	15.54	2.28	15.33	2.07	0.35
Width of lower airway, mm	11.31	2.15	12.63	1.74	0.005

test showed a statistically significant correlation between the presence of more than 1 pathology (the hypertrophy of the adenoids, the hypertrophy of the tonsils, the nasal septum deviation, allergic rhinitis, or/and thoracic kyphosis) and the increase in the MP-SN angle and the decrease in the SNB angle. Many previous studies have shown that the nasopharyngeal pathology, which causes mouth breathing, might also cause changes in the head posture, changes in the growth of the mandible (which rotates downward and backward), and an increased lower face height (33). An altered neck posture was observed in 80.0% of the mouth-breathing children (29). However, Neiva et al. did not find any increase in thoracic kyphosis measurements in the group of mouth breathers (32).

When evaluating the body posture in a transversal plane, a correlation was found between a higher overbite and the asymmetry of the shoulders and the scapulae. We did not find any relation between the body posture, the nasopharyngeal pathology, and crowding in the dental arches or the posterior cross bite, although, in literature, mouth breathing is associated with the narrowing of the upper dental arch and the posterior cross bite (19). This is also in

contrast to the findings of Pachi et al., as well as Sollow and Sonnesen, who stated that crowding was associated with the craniocervical posture and greater than 2-mm dental crowding in the dental arches increased the craniocervical angles by 3°–6° (13, 14). Whereas Micheloti et al. stated that the unilateral posterior cross bite did not influence postural stability and the treatment of this malocclusion to prevent or to treat postural disorders was not justified (5).

No relationship between the orthodontic parameters and the orthopedic anomalies in the lower thoracic regions was found. Contrary, Lippold et al. discovered that the vertical and the sagittal mandibular position correlated with lower pelvic angles, the pelvic torsion, and the body posture. However, the position of the maxilla did not correlate with spinal curvatures (20–23). Conflicting results of the studies can be explained, at least in part, by methodological differences of the study design (type of orthopedic evaluation and different age of patients).

In summary, the results of the present study suggest that the most significant associations were found between the nasopharyngeal pathology, the increase in the MP-SN angle, and the kyphotic posture. The question of causality remains, i.e., which morpho-

logical changes were primary and which were the consequences? The functional matrix theory by Moss says that the craniofacial bony growth occurs as a reaction to the functional matrix (muscle, soft tissue, teeth, as well as the functioning volumes of various cavities) surrounding it. Solow explains the changes in craniofacial morphology by the soft tissue stretching mechanism (19). This mechanism postulates that the soft tissue layer of the facial skin and the muscles exerts forces on the facial skeleton. In cases of airway obstruction, the head is extended in relation to the cervical column; the soft tissue layer then would be passively stretched. This stretching of the soft tissue of the head and the neck creates a dorsal force, which, in turn, impedes the forward growth of the face, particularly the mandible. From the results of the present study, it is possible to simulate that in cases of airway obstruction not only the posture of the head but also the body posture changes. Therefore, good body posture and the function of the airway is of considerable importance in orthodontics and cannot be overlooked in treatment planning.

References

1. Kratenová J, Zejglicová K, Malý M, Filipová V. Prevalence and risk factors of poor posture in school children in the Czech Republic. *J Sch Health* 2007;77:131-7.
2. Hefti F, Breuner R, Hasler C, Jundt G. *Pediatric orthopedics in practice*. Berlin: Springer-Verlag; 2007. p. 67-71.
3. Bracco P, Deregis A, Piscetta R. Effects of different jaw relations on postural stability in human subjects. *Neurosci Lett* 2004;356:228-30.
4. Cuccia AM. Interrelationships between dental occlusion and plantar arch. *J Bodyw Mov Ther* 2011;15:242-50.
5. Michelotti A, Buonocore G, Farella M, Pellegrino G, Piergentili C, Altobelli S, et al. Postural stability and unilateral posterior crossbite: Is there a relationship? *Neurosci Lett* 2006;392:140-4.
6. Maeda N, Sakaguchi K, Mehta NR, Abdallah EF, Forgione AG, Yokoyama A. Effects of experimental leg length discrepancies on body posture and dental occlusion. *Cranio* 2011;29:194-203.
7. Perinetti G. Dental occlusion and body posture: no detectable correlation. *Gait Posture* 2006;24:165-68.
8. Perinetti G, Contardo L, Biasati AS, Perdoni L, Castaldo A. Dental malocclusion and body posture in young subjects: a multiple regression study. *Clinics (Sao Paulo)* 2010;65:689-95.
9. Tardieu C, Dumitrescu M, Giraudeau A, Blanc JC, Cheynet F, Borel L. Dental occlusion and postural control in adults. *Neurosci Lett* 2009;450:221-4.
10. Motoyoshi M, Shimazaki T, Sugai T, Namura S. Biomechanical influences of head posture on occlusion: an experimental study using finite element analysis. *Eur J Orthod* 2002;24:319-26.
11. Hanke BA, Motschall E, Türp JC. Association between orthopedic and dental findings: what level of evidence is available? *J Orofac Orthop* 2007;68:91-107.
12. D'Attilio M, Caputi S, Epifania E, Festa F, Tecco S. Evaluation of cervical posture of children in skeletal class I, II, and III. *Cranio* 2005;23:219-28.
13. Pachi F, Turla R, Checchi AP. Head posture and lower arch dental crowding. *Angle Orthod* 2009;79:873-80.
14. Solow B, Sonnesen L. Head posture and malocclusions. *Eur J Orthod* 1998;20:685-93.
15. Arntsen T, Sonnesen L. Cervical vertebral column morphology related to craniofacial morphology and head posture in preorthodontic children with Class II malocclusion and horizontal maxillary overjet. *Am J Orthod Dentofacial Orthop* 2011;140:e1-7.
16. Di Vece L, Faleri G, Picciotti M, Guido L, Giorgetti R. Does a transverse maxillary deficit affect the cervical vertebrae? A pilot study. *Am J Orthod Dentofacial Orthop* 2010;137:515-9.
17. Sonnesen L, Bakke M. Molar bite force in relation to occlusion, craniofacial dimensions, and head posture in preorthodontic children. *Eur J Orthod* 2005;27:58-63.
18. Sonnesen L, Pedersen C, Kjær I. Cervical column morphology related to head posture, cranial base angle and condylar malformation. *Eur J Orthod* 2007;29:1-6.
19. Solow B, Sandham A. Cranio-cervical posture: a factor in the development and function of the dentofacial structures. *Eur J Orthod* 2002;24:447-56.
20. Lippold C, Van Den Bos L, Hohoff A, Danesh G, Ehmer U. Interdisciplinary study of orthopedic and orthodontic findings in pre-school infants. *J Orofac Orthop* 2003;64:330-40.
21. Lippold C, Danesha G, Hoppe G, Drerup B, Hackenberg L. Sagittal spinal posture in relation to craniofacial morphology. *Angle Orthod* 2006;76:625-32.
22. Lippold C, Danesha G, Schilgen M, Drerup B, Hackenberg L. Relationship between thoracic, lordotic, and pelvic inclination and craniofacial morphology in adults. *Angle Orthod* 2006;76:779-6.
23. Lippold C, Danesha G, Hoppe G, Drerup B, Hackenberg L. Trunk inclination, pelvic tilt and pelvic rotation in relation to the craniofacial morphology in adults. *Angle Orthod* 2007;77:29-35.
24. Perillo L, Signoriello G, Ferro F, Baccetti T, Masucci C, Apicella D, et al. Dental occlusion and body posture in growing subjects. A population-based study in 12-year-old Italian adolescents. *Int Dent SA* 2008;10:46-52.
25. Ben-Bassat Y, Yitschaky M, Kaplan L, Brin I. Occlusal

Conclusions

The prevalence of the poor body posture and the nasopharyngeal pathology was very high in the present study. In total, 48.7% of the orthodontic patients had the kyphotic posture. The nasopharyngeal pathology was diagnosed in 78.9% of the patients. The evaluation of the correlation between the type of the orthodontic anomalies and the body posture showed a significant correlation between the sagittal position of the mandible (SNB angle) and the mandibular plane angle (MP-SN) and the kyphotic posture, i.e., the patients with the kyphotic posture had higher MP-SN angles and lower SNB angles. A relationship between the nasopharyngeal pathology and the body posture was found, i.e., thoracic kyphosis was more common among the patients with the nasopharyngeal pathology. The study showed no relationship between the degree of crowding, the presence of the posterior cross bite, and the sagittal and the transversal orthopedic parameters.

Statement of Conflict of Interest

The authors state no conflict of interest.

- patterns in patients with Idiopathic scoliosis. *Am J Orthod Dentofacial Orthop* 2006;130:629-33.
26. Segatto E, Lippold C, Véggh A. Craniofacial features of children with spinal deformities. *BMC Musculoskelet Disord* 2008;9:169-79.
 27. Harila V, Valkama M, Sato K, Tolleson S, Hanis S, Kau CH, et al. Occlusal asymmetries in children with congenital hip dislocation. *Eur J Orthod* 2012;34:307-11.
 28. Ikemitsu H, Zeze R, Yuasa K, Izumi K. The relationship between jaw deformity and scoliosis. *Oral Radiol* 2006;22:14-7.
 29. Okuro RT, Morcillo AM, Sakano E, Schivinski CIS, Ribeiro MA, Ribeiro JD. Exercise capacity, respiratory mechanics and posture in mouth breathers. *Braz J Otorhinolaryngol* 2011;77:656-62.
 30. Tecco S, Festa F, Tete S, Longhi V, D'Attilio M. Changes in head posture after rapid maxillary expansion in mouth-breathing girls: a controlled study. *Angle Orthod* 2005;75:171-6.
 31. McGuinness NJ, McDonald JP. Changes in natural head position observed immediately and one year after rapid maxillary expansion. *Eur J Orthod* 2006;28:126-34.
 32. Neiva PD, Kirkwood RN, Godinho R. Orientation and position of head posture, scapula and thoracic spine in mouth-breathing children. *Int J Pediatr Otorhinolaryngol* 2009;73:227-36.
 33. Cuccia AM, Lotti M, Caradonna D. Oral breathing and head posture. *Angle Orthod* 2008;78:77-82.
 34. Proffit WR, Fields HW, Sarver DM. *Contemporary orthodontics*. 4th ed. St Louis, MO: Mosby Elsevier; 2007. p. 167-268.
 35. McNamara JA, Brudon WL. *Orthodontic and orthopedic treatment in the mixed dentition*. Ann Arbor, Mich: Needham Press; 1993. p. 42-4.
 36. Wormald PJ, Prescott CA. Adenoids: comparison of radiological assessment methods with clinical and endoscopic findings. *J Laryngol Otol* 1992;106:342-4.
 37. Friedman M, Tanyeri H, La Rosa M, Landsberg R, Vaidyanathan K, Pieri S, et al. Clinical predictors of obstructive sleep apnea. *Laryngoscope* 1999;109:1901-7.
 38. Hefti FL, McMaster MJ. The effect of the adolescent growth spurt on early posterior spinal fusion in infantile and juvenile idiopathic scoliosis. *J Bone Joint Surg Br* 1983;65:247-54.
 39. Largo RH, Gasser T, Prader A, Stuetzle W, Huber PJ. Analysis of the adolescent growth spurt using smoothing spline functions. *Ann Hum Biol* 1978;5:421-34.
 40. Abreu RR, Rocha RL, Lamounier JA, Guerra AFM. Prevalence of mouth breathing among children. *J Pediatr (Rio J)* 2008;84:467-70.
 41. Kawashima S, Peltomäki T, Sakata H, Mori K, Happonen RP, Rönning O. Craniofacial morphology in preschool children with sleep-related breathing disorder and hypertrophy of tonsils. *Acta Paediatr* 2002;91:71-7.

Received 7 April 2013, accepted 29 November 2013